


# AIRTRAQ<sup>®</sup>

## GUIDED VIDEO INTUBATION

# Clinical Communications Summary

## May 2010



**Clinical Studies**  
**Case Reports**  
**Letters to the Editor**  
**Manikin Studies**

# Clinical Communications by Subject

## Index

	<u>Pages</u>
1. General Studies	1-22
2. Difficult Airways	23-33
3. Obese & Obstetrics patients	34-41
4. Awake patients	42-52
5. Trauma, Bleeding & C-spine Immobilization	53-65
6. Prehospital & Military	66-82
7. Special Procedures	83-90
8. Pediatrics	91-100
9. Nasotracheal	101-107
10. Double Lumen / B. Blocker	108-110
11. Techniques & Learning Curve	111-124
12. Airtraq vs. Other Video Laryngoscopies	125-134

# 1. General Studies

CLINICAL STUDIES					
Ref	Title	Published	Performed By	Hospital	Country
CS#1	A comparison of tracheal intubation using the Airtraq or the Macintosh laryngoscope in routine airway management: A randomised, controlled clinical trial.	Anaesthesia. 2006 Nov;61(11):1093-9.	Maharaj CH et Al.	Univ. Of Ireland, Galway	Ireland
CS#3	The Macintosh Laryngoscope vs. the New Airtraq Device	Journal Watch Emergency Medicine November 3, 2006	Aaron E. Bair,MD,	Dep. of Emergency Medicine at the Univ. of California	USA
CS#4	Endotracheal Intubation in Patients with Cervical Spine Immobilization. A Comparison of Macintosh and Airtraq Laryngoscopes.	Anesthesiology 2007; 107:53–9	Maharaj CH et Al.	Univ. Of Ireland, Galway	Ireland
CS#7	Evaluation of the Airtraq and Macintosh laryngoscopes in patients at increased risk for difficult tracheal intubation	Anaesthesia, 2008, 63, pages 182–188	Maharaj CH et Al.	Univ. Of Ireland, Galway	Ireland
CS#8	The Airtraq Optical Laryngoscope: Experiences with a New Disposable Device for Orotracheal Intubation.	Anaesthesia, 2008, 63, pages 1387–1391	K. Krasser,	Empress Elisabeth Hospital Vienna	Austria

# 1. General Studies

CLINICAL STUDIES					
CS#12	Tracheal intubation of morbidly obese patients: a randomized trial comparing performance of Macintosh and Airtraq laryngoscopes.	British Journal of Anaesthesia 100 (2): 263–8 (2008)	S. K. Ndoko et Al.	Jean Verdier Public University Hospital of Paris	France
CS#13	Success of Orotracheal Intubation with the Airtraq Optical Laryngoscope in Patients with Difficult Conventional Laryngoscopy	Internet Journal of Airway Management Volume 5	Zadrobilek E.	Empress Elisabeth Hospital Vienna	Austria
CS#14	Airtraq tracheal intubation by novice laryngoscopists	Emergency Medicine Journal 2009; 26; 112-113	Y. Hirabayashi, MD and N.Seo, MD	Jichi Medical University	Japan
CS#21	Teaching and Training of Non Anaesthesia Residents in Orotracheal Intubation with the Airtraq Wireless Monitor	Internet Journal of Airway Management Volume 5 (January 2008 to December 2009)	Schirin M. Missaghi, MD	Empress Elisabeth Hospital Vienna	Austria

LETTERS TO THE EDITOR					
Ref	Title	Published	Performed By	Hospital	Country
LE#1	Use of the Disposable Airtraq Optical Laryngoscope for Orotracheal Intubation in Patients with Infectious Diseases.	Internet Journal of Airway Management Volume 4	Schirin M. Missaghi, MD	Empress Elisabeth Hospital Vienna	Austria
LE#2	The Role of Newer Intubation Devices in Difficult Intubation Protocols: A Pan Birmingham Survey.		S Gnanaseakaran	Royal Centre for Defence Medicine, Birmingham.	UK
LE#3	Advantages of The Airtraq Laryngoscope.	The Internet Journal of Medical Technology ISSN: 1559: 4610	Gerald Mays	East Tennessee State University.	USA

# 1. General Studies

MANIKIN STUDIES					
Ref	Title	Published	Performed By	Hospital	Country
MS#1	Evaluation of intubation using the Airtraq or Macintosh laryngoscope by anaesthetists in easy and simulated difficult laryngoscopy--a manikin study.	Anaesthesia. 2006 May;61(5):469-77	Maharaj CH et Al.	Univ. Of Ireland, Galway	Ireland
MS#4	Use of the Airtraq laryngoscope in a model of difficult intubation by prehospital providers not previously trained in laryngoscopy.	Anaesthesia, 2007, 62, pages 1061–1065	M. Woollard	Australian College of Ambulance Professionals	Australia
MS#5	Airtraq vs standard laryngoscopy by student paramedics and experienced prehospital laryngoscopists managing a model of difficult intubation*	Anaesthesia, 2008, 63, pages 26–31 doi:10.1111/j.1365-2044.	M. Woollard	Australian College of Ambulance Professionals	Australia
MS#10	Comparison of the Glidescope , the McGrath , the Airtraq and the Macintosh laryngoscopes in simulated difficult airways* G. L.	Anaesthesia, 2008, 63, pages 1358–1364	Savoldelli et Al.	University of Geneva	Switzerland
MS#15	Airtraq advantage for presbyopic anaesthetists	Anaesthesia, 2010, 65, pages 306–315	Y. Imashuku	Seta Tsukinowa-Cho, Otsu, Shiga	Japan

# CS#1

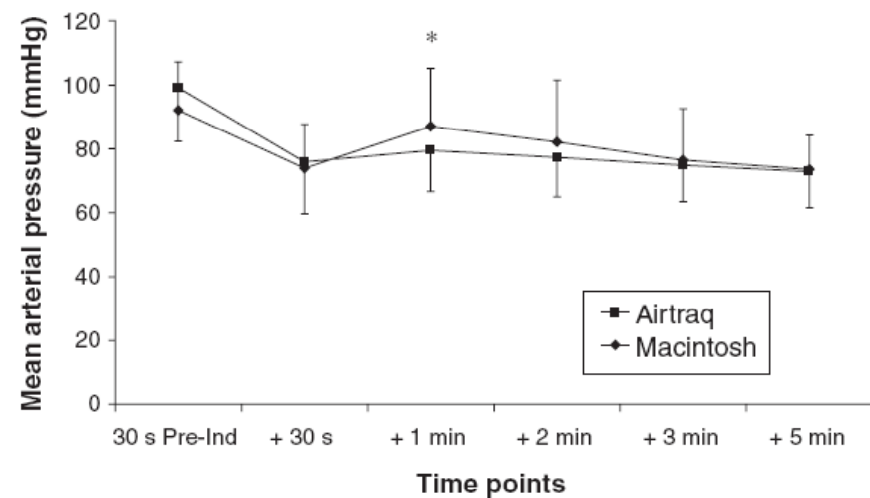
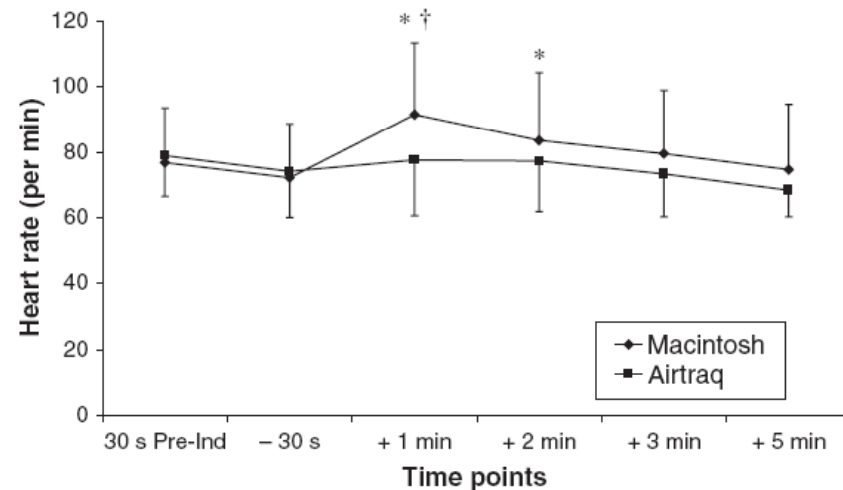
## **A comparison of tracheal intubation using the Airtraq or the Macintosh laryngoscope in routine airway management: a randomized, controlled clinical trial**

Anaesthesia, 2006; 61:1093-1099. Maharaj CH et Al. Univ. Of Ireland, Galway

**Sixty** consenting patients presenting for surgery requiring tracheal intubation were randomly allocated to undergo intubation using a Macintosh (n ¼ 30) or Airtraq (n ¼ 30) laryngoscope.

**The Airtraq provides comparable or superior intubating conditions in the normal airway.** There was no difference between groups in the degree of success of intubation attempts, or in the duration of time required to perform tracheal intubation. However, **the Airtraq device did reduce intubation difficulty.**”

“Tracheal intubation with the AIRTRAQ resulted in **less alterations in heart rate**, which demonstrates the utility of the AIRTRAQ laryngoscope for tracheal intubation.”



# CS#3

## **The Macintosh Laryngoscope vs. the New Airtraq Device**

*JournalWatch Emergency Medicine November 3, 2006.*

Aaron E. Bair, MD, Dep. of Emergency Medicine at the Univ. of California

**Sixty adults** were enrolled. **All patients in the Airtraq group and all but one in the Macintosh group were intubated on the first attempt**, but the mean intubation difficulty score was significantly lower in the Airtraq group (0.2 vs. 1.4, respectively, with 0 representing perfect intubation). Time to intubation did not differ between the groups. Anesthetists rated the Airtraq easier to use than the Macintosh laryngoscope (mean scores of 1.2 vs. 2.0 on a 0–10 visual analog scale).

**The authors conclude that in patients with normal airways, the Airtraq is easier to use and provides intubating conditions that are comparable or superior to those of the Macintosh laryngoscope.**

**Comment:** Direct laryngoscopy is unnecessarily difficult and traumatic for the upper airway, and its development predated modern optics. **The time has come to retire the beloved metal laryngoscope —it has served its purpose, and many superior options are now available.**

## CS#4

### **Endotracheal Intubation in Patients with Cervical Spine Immobilization** **A Comparison of Macintosh and Airtraq Laryngoscopes**

Anesthesiology 2007; 107:53–9. Maharaj CH et Al. Univ. Of Ireland, Galway

The Airtraq reduced the duration of intubation attempts (mean SD: 13.2 5.5 vs. 20.3 12.2 s), the need for additional manoeuvres, and the intubation difficulty scale score (0.1 0.5 vs. 2.7 2.5). Tracheal intubation with the Airtraq caused fewer alterations in blood pressure and heart rate.

Conclusions: **These findings demonstrate the utility of the Airtraq laryngoscope for tracheal intubation in patients with cervical spine immobilization.**

**Table 3. Data for Intubation Attempts with Each Device**

Parameter Assessed	Macintosh	Airtraq
Overall success rate (%)	19 (95)	20 (100)
Intubation difficulty scale score	2 (0.3)	0 (0.0)†
Duration of intubation attempt, s	20.3 ± 12.2	13.2 ± 5.4*
Lowest SpO <sub>2</sub> during intubation attempt, %	98.7 ± 1.4	99.4 ± 0.7
No. of intubation attempts (%)		
1	19 (95)	20 (100)
2	0	0
3	1 (5)	0
No. of optimization maneuvers (%)		
0	12 (60)	20 (100)*
1	5 (25)	0
≥ 2	3 (15)	0



# CS #7

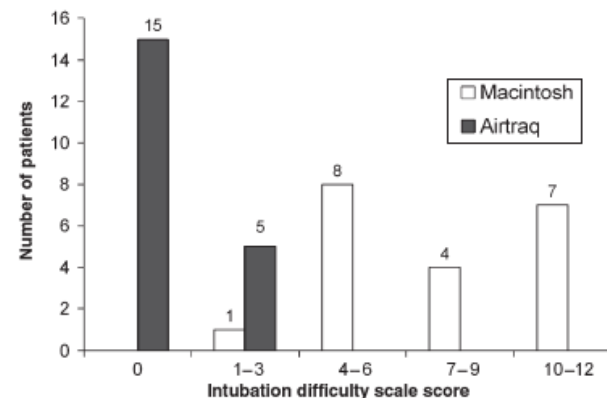
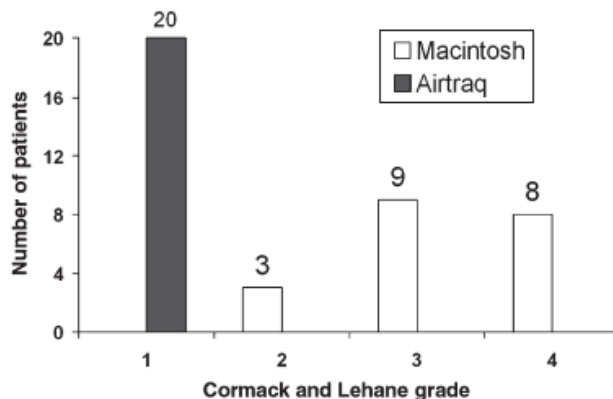
## Evaluation of the Airtraq and Macintosh laryngoscopes in patients at increased risk for difficult tracheal intubation\*

Anaesthesia, 2008, 63, pages 182–188. Maharaj CH et Al. Univ. Of Ireland, Galway

**Forty consenting patients**, who were deemed to possess at least three characteristics indicating an **increased risk for difficulty** in tracheal intubation, were randomly assigned to undergo tracheal intubation using a Macintosh (n = 20) or Airtraq (n = 20) laryngoscope.

**Four patients were not successfully intubated with the Macintosh laryngoscope, but were intubated successfully with the Airtraq.** The Airtraq reduced the duration of intubation attempts (mean (SD); 13.4 (6.3) vs 47.7 (8.5) s), the need for additional manoeuvres, and the intubation difficulty score (0.4 (0.8) vs 7.7 (3.0)).

Tracheal intubation with the Airtraq also **reduced the degree of haemodynamic stimulation and minor trauma** compared to the Macintosh laryngoscope.



## CS#8

### **The Airtraq Optical Laryngoscope: Experiences with a New Disposable Device for Orotracheal Intubation**

Anaesthesia, 2008, 63, pages 1387–1391

K. Krasser, Empress Elisabeth Hospital of the City of Vienna

Seven staff anaesthetists and two residents were novice users of the AOL. They first received formal hands-on training, and performed AOL-assisted laryngoscopy and tracheal intubation attempts on **100 patients**. Grades 1 to 5 at CLV were obtained in 36, 26, 16, 10, and 2 patients, respectively.

The success rate of AOL-assisted tracheal intubation at the **first attempt was 98%** with laryngeal views of grade 1 in all of these patients. Two patients required a second attempt, the causes were failed identification of anatomical structures and failed TT advancement during laryngeal passage. The laryngeal views obtained with the AOL during the second attempt were grade 1 in both patients. **In all patients, AOL-assisted tracheal intubation was successful (after a maximum of two attempts).**

**Following formal instruction, success of tracheal intubation with the AOL performed by novice users was not affected by CLV. The AOL proved to be uniquely useful for routine and difficult laryngoscopy and tracheal intubation.**

# CS#12

## **Tracheal intubation of morbidly obese patients: a randomized trial comparing performance of Macintosh and Airtraq**

British Journal of Anaesthesia 100 (2): 263–8 (2008)

S. K. Ndoko et Al. Jean Verdier Public University Hospital of Paris

**One hundred and six** consecutive ASA I–III morbidly obese patients undergoing surgery were randomized to intubation with the Macintosh laryngoscope or the Airtraq laryngoscope.

**In the Airtraq group, tracheal intubation was successfully carried out in all patients within 120 s. In the Macintosh laryngoscope group, six patients required intubation with the Airtraq laryngoscope.**

The mean (SD) time taken for tracheal intubation was 24 (16) and 56 (23) s, respectively, with the Airtraq and Macintosh laryngoscopes, (P,0.001). SpO<sub>2</sub> was better maintained in the Airtraq group than in the Macintosh laryngoscope group with one and nine patients, respectively, demonstrating drops of SpO<sub>2</sub> to 92% or less (P,0.05).

**Conclusions.** In this study, the Airtraq laryngoscope shortened the duration of tracheal intubation and prevented reductions in arterial oxygen saturation in morbidly obese patients.

# CS#13

## **Success of Orotracheal Intubation with the Airtraq Optical Laryngoscope in Patients with Difficult Conventional Laryngoscopy.**

Internet Journal of Airway Management Volume 5 (January 2008 to December 2009).

Zadrobilek E.

**312 patients** for elective **thyroid surgical procedures** with various conventional laryngoscopic views. **Further 20 patients** with difficult conventional laryngoscopy (CL) also for elective thyroid surgery attempted by using the AOL were additionally included in this clinical review.

In the 332 patients evaluated, **grade 1 to 5 at CL was obtained in 111, 90, 61, 68, and 2 patients, respectively.** The overall success rate of AOL-assisted tracheal intubation at the **first attempt was 98 percent; in all patients, tracheal intubation was successful after a maximum of two attempts.**

**In the 70 patients with difficult CL (grade 4 or 5), the success rate of AOL-assisted tracheal intubation at the first attempt was 94 percent (66/70 patients).** The causes of primary failures of tracheal intubation were failed identification of anatomical structures (in one patient) and failed tracheal tube (TT) advancement during laryngeal passage (in 3 patients). Visualization of the entire laryngeal aperture was finally obtained in all patients; downsized TTs for atraumatic tracheal intubation were required in 2 patients.

# CS#14

## **Airtraq tracheal intubation by novice laryngoscopists**

*Emerg. Med. J.* 2009;26;112-113113doi:10.1136/emj.2008.059659

Yoshihiro Hirabayashi, Norimasa Seo, Jichi Medical University, Japan

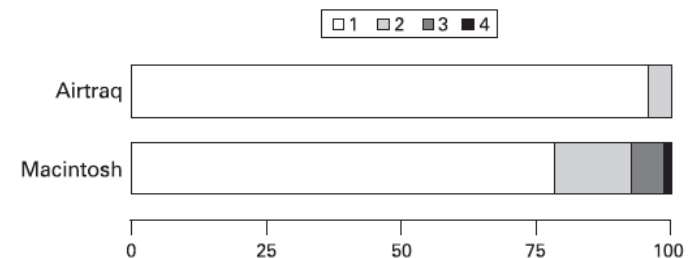
Under supervision by staff anaesthetists, **nonanaesthesia physicians** performed tracheal intubation using either the **Airtraq (n = 100)** or the Macintosh laryngoscope (n = 100).

The **time to secure the airway was shorter with the Airtraq** than with the Macintosh laryngoscope (p,0.001).

The **number of attempts until successful intubation was smaller with the Airtraq** than with the Macintosh laryngoscope (p,0.001).

**Erroneous oesophageal intubation was less with the Airtraq optical laryngoscope** than with the Macintosh laryngoscope (p,0.01).

Differences in tracheal intubation procedure using the Airtraq and Macintosh laryngoscopes by non-anaesthesia novice physicians			
	Airtraq	Macintosh	p Value
Time to intubation, in seconds (SD)*	51 (17)	67 (43)	0,001
Erroneous intubation of the oesophagus	0	10	0,01



**Figure 2** The number of attempts until successful intubation using the Airtraq and Macintosh laryngoscope by non-anaesthesia novice physicians. Mann–Whitney U test showed the significant difference between the two groups (p<0.001).

# CS#21

## **Teaching and Training of Non Anaesthesia Residents with the Airtraq using the Airtraq Wireless Monitor for Instruction**

Internet Journal of Airway Management Volume 5 (January 2008 to December 2009)

Missaghi SM, , Austria

**Sixty four adult patients undergoing elective thyroid surgical procedures** were investigated. Patients with a previously experienced difficult conventional tracheal intubation, anatomic features predictive for difficult CL and tracheal intubation, and/or obesity were given referential enrollment into the study. The operators (3 emergency medicine residents and one surgical resident) had less experiences with AM techniques on patients and were novice users of the Airtraq.

Grades 1 to 4 at CL were obtained in 25, 16, 13, and 10 patients, respectively. **The success rate of Airtraq assisted tracheal intubation at the first attempt was 100 percent (64/64 patients).** Provided formal instruction (supported by the AWM) and supervision, the success of Airtraq assisted orotracheal intubation performed by nonanesthesia residents was not affected by CLV. **For operators responsible for emergency AM with less experiences and opportunities in these techniques, the Airtraq may be uniquely useful for routine and difficult laryngoscopy and tracheal intubation.**

# LE#1

## **Use of the Disposable Airtraq Optical Laryngoscope for Orotracheal Intubation in Patients with Infectious Diseases**

Internet Journal of Airway Management

Schirin M. Missaghi, MD. Empress Elisabeth Hospital Vienna

Hygienic reprocessing of reusable airway management devices may be problematic, particularly after use in patients with transferable infectious diseases.

Fourteen patients (including two with anatomic features predictive for difficult conventional laryngoscopy and tracheal intubation) are now included in this evaluation. AOL-assisted tracheal intubation with standard tracheal tubes was successful at the first attempt with laryngeal views of the entire laryngeal aperture. **This procedure may further eliminate possible cross contamination with reusable airway devices.**

Recently, three video laryngoscope systems with dedicated disposable laryngoscope blades (supplied in sterile packaging) were launched: the AirWay Scope, the GlideScope Cobalt Video Laryngoscope and the McGrath Portable Video Laryngoscope

They may be less suitable in this patient population because **the reusable handles (and the camera systems) may become contaminated during the laryngoscopy and tracheal intubation process and their thorough hygienic reprocessing is limited.**

## LE#2

### **The role of newer intubation devices in difficult intubation protocols: a Pan Birmingham survey.**

S Gnanaseakaran. Royal Centre for Defence Medicine, Birmingham.

This Pan Birmingham survey was designed to establish which devices are being used, the level of training in their use and whether newer intubation devices have been incorporated into local difficult intubation protocols.

**Methods.** 108 questionnaires were sent.

**Conclusions.** In Birmingham, fiberoptic endoscopy remains the preferred method of managing the 'can mask ventilate, can't intubate' patient. The ILMA was not felt to be particularly easy to use, less than half of the anaesthetists surveyed were trained to use it and it featured in less than 50% of the secondary intubation plans.

Of the newer intubation devices **the Airtraq (30%) was the preferred second choice method of managing difficult intubation.**

**We anticipate that once their value has been proven, these newer intubation devices and techniques will feature in the DAS list of recommended equipment for management of difficult intubation.**



## LE#3

### **Advantages Of The Airtraq Laryngoscope**

Gerald Mays, RRT East Tennessee State University, USA

**Conclusions :** Research cited previously indicates that the **Airtraq is a step forward in airway management**. The studies cited in this paper indicate that the Airtraq laryngoscope is **superior to the Macintosh** in every situation evaluated and was deemed **easier to use** by all personnel used in these evaluations. The advantage provided by the Airtraq lies in its' ability to provide a clear view of the glottis without alignment of the oropharyngeal axes.

At a cost of around eighty dollars for a single use disposable device this would seem to be **a small price to pay for the advantages offered**. When the cost of maintaining a reusable laryngoscope, sterilization of blades and the inherent infection control issues are considered the cost of the Airtraq laryngoscope becomes less of an issue.

**Recommendations :** The Airtraq laryngoscope is a device which should be made available to all departments and or entities where intubations may be preformed. This device has proven to be superior to other known devices of this type and would afford better results by a variety of users with a wide range of experience.

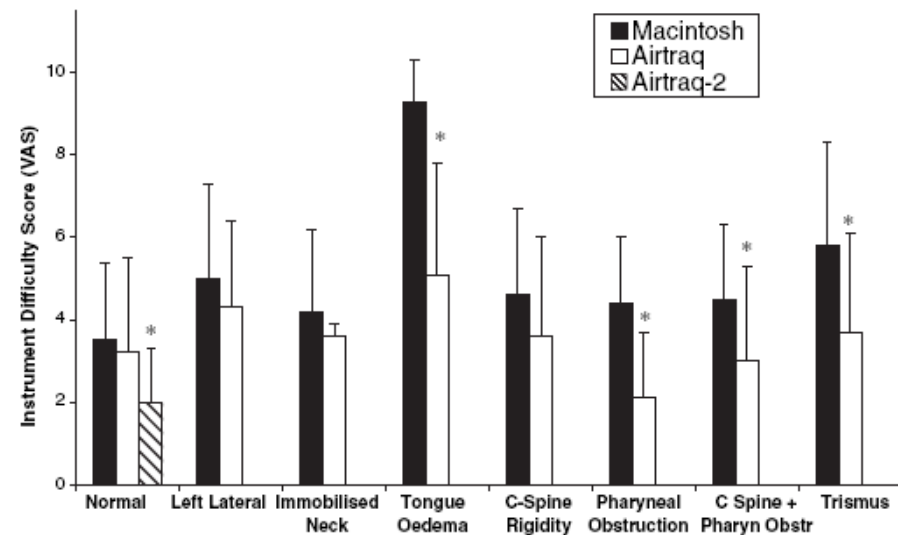
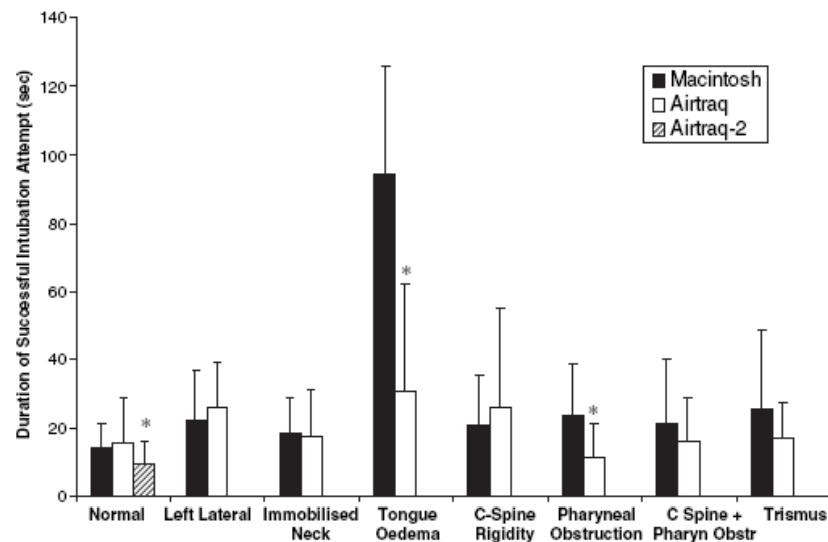
# MS#1

## **Evaluation of intubation using the Airtraq or Macintosh laryngoscope by anaesthetists in easy and simulated difficult laryngoscopy – a manikin study\***

Anaesthesia, 2006; 51:469-477.

Maharaj CH et Al. Univ. Of Ireland, Galway

In the simulated difficult laryngoscopy scenarios, the AIRTRAQ was **more successful** in achieving tracheal intubation, required **less time to intubate** successfully, caused **less dental trauma**, and was considered by the anaesthetists to be **easier to use**.



# MS#4

## **Use of the Airtraq laryngoscope in a model of difficult intubation by prehospital providers not previously trained in laryngoscopy**

Anaesthesia, 2007, 62, pages 1061–1065

Our study results suggest that this new laryngoscope **can facilitate high rates of successful intubation in particularly challenging circumstances** represented by a combination of practitioners with only 5 min laryngoscopy training presented with a model of a Cormack and Lehane grade III/IV view.

**The Airtraq may therefore offer an effective tool to improve first-time intubation success rates and reduce the incidence of misplaced tracheal tubes** when used by trained advanced life support providers working in the testing environment of the prehospital setting.

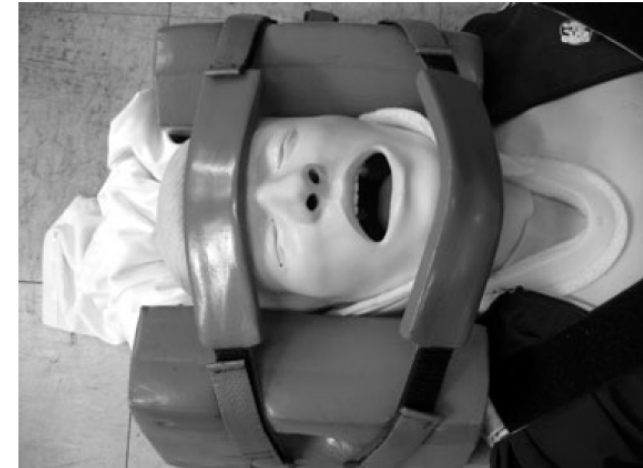

Figure 3 Manikin model of difficult intubation.

# MS#5

## *Airtraq vs standard laryngoscopy by student paramedics and experienced prehospital laryngoscopists managing a model of difficult intubation\**

Anaesthesia, 2008, 63, pages 26–31

M. Woollard. Australian College of Ambulance Professionals

The first of two studies reported in this paper aimed to determine whether use of the Airtraq by pre-employment third-year student paramedics resulted in improved intubation success rates compared with standard laryngoscopy in a manikin model of a Cormack and Lehane grade III/IV laryngoscopic view.

The second study compared the intubation success rates of experienced prehospital laryngoscopists when managing the same model of a difficult intubation using either an Airtraq or a Macintosh laryngoscope.

The studies reported in this paper have demonstrated that, **in a manikin model of difficult intubation, both student paramedics and experienced prehospital laryngoscopists rate the Airtraq as significantly easier to use than a Macintosh laryngoscope with a malleable stylet after minimal additional training.**

**Both groups achieved significantly higher first-time intubation success rates and significantly fewer failed and oesophageal intubations with the Airtraq device.**

# MS#10

## **Comparison of the Glidescope, the McGrath, the Airtraq and the Macintosh laryngoscopes in simulated difficult airways**

Anaesthesia, 2008, 63, pages 1358–1364

Savoldelli et Al. University of Geneva

Sixty anaesthesia providers (20 staff, 20 residents, and 20 nurses) were enrolled into this study. The volunteers intubated the trachea of a **Laerdal SimMan manikin in three simulated difficult airway scenarios.**

In all scenarios, indirect laryngoscopes provided better laryngeal exposure than the Macintosh blade and appeared to produce less dental trauma.

In the most difficult scenario (tongue oedema), the Macintosh blade was associated with a high rate of failure and prolonged intubation times whereas indirect laryngoscopes improved intubation time and rarely failed. Indirect laryngoscopes were judged easier to use than the Macintosh.

**The Airtraq consistently provided the most rapid intubation. Laryngeal grade views were superior with the Airtraq and McGrath than with the Glidescope.**

# MS#15

## **Airtraq® optical laryngoscope has an advantage over Macintosh laryngoscope for presbyopic anaesthetists**

Anaesthesia, 2010,65,pages 306-315

Y. Imashuku, Tsukinowa-Cho, Otsu, Shiga, Japan

We investigated the time required for an accurate reading of the Landolt ring mark (diameter approximately 2.5 mm) for visual acuity testing in front of the vocal cords of an intubation training manikin.

We measured the time from moving the eyes from an anaesthetic monitor placed approximately 2 m away to reading the Landort ring mark in front of the glottis exposed by an Airtraq or Macintosh laryngoscope.

Less time was required to reach the correct answer using the Airtraq compared with the Macintosh laryngoscope in the presbyopic group (2.8 (0.7) s vs 6.2 (3.2) s, respectively,  $p < 0.05$  using Student's t test).

**These results suggest that in the presbyopic group, the magnified observation using the Airtraq makes it faster to read a Landolt ring mark placed in front of the vocal cords compared with direct observation using Macintosh laryngoscope.**

## 2. Difficult Airways

CLINICAL STUDIES					
Ref	Title	Published	Performed By	Hospital	Country
CS#2	Laryngoscopy vs. Optical Stylet vs. Optical Laryngoscope (Airtraq) for Extubation Evaluation.	American Society of Anesthesiologists October 14-18, 2006	T.C. Mort, M.D.	Hartford Hospital	USA
CS#7	Evaluation of the Airtraq and Macintosh laryngoscopes in patients at increased risk for difficult tracheal intubation	Anaesthesia, 2008, 63, pages 182–188	Maharaj CH et Al.	Univ. Of Ireland, Galway	Ireland
CS#8	The Airtraq Optical Laryngoscope: Experiences with a New Disposable Device for Orotracheal Intubation.	Anaesthesia, 2008, 63, pages 1387–1391	K. Krasser,	Empress Elisabeth Hospital Vienna	Austria
CS#13	Success of Orotracheal Intubation with the Airtraq Optical Laryngoscope in Patients with Difficult Conventional Laryngoscopy	Internet Journal of Airway Management Volume 5	Zadrobilek E.	Empress Elisabeth Hospital Vienna	Austria
CS#26	An Investigation into Usefulness of Direct Optical Laryngoscope in Patients with Difficult Airways	2011 ASA Abstracts	Neal Samuels, F.R.C.A	St. Bartholomews' Hospital, West Smithfield	UK

CASE REPORTS					
Ref	Title	Published	Performed By	Hospital	Country
CR#5	The Airtraq as a rescue airway device following failed direct laryngoscopy: a case series.	Anaesthesia, 2007, 62, pages 598–601.	Maharaj CH et Al.	Univ. Of Ireland, Galway	Ireland
CR#11	Use of the Airtraq as the primary technique to manage anticipated difficult airway: a report of three cases.	Journal of Clinical Anesthesia (2008) 20, 474-477.	Savoldelli et Al.	University of Geneva	Switzerland
CR#14	Use of the Airtraq with fiberoptic bronchoscope in a difficult intubation outside the operating room.	Canadian Journal of Anesthesia 55:8 August 2008.	Adrian A. Matic md,	University of Wisconsin Hospital	USA
CR#18	Use of the Airtraq® in the difficult airway	European Journal of Anaesthesiology 24: 720–732.	P. N. R. Ford; C. Hamer, S. Medakkar	Royal Devon and Exeter Hospital Torquay,	UK
CR#19	Use of the nasotracheal Airtraq® to assist difficult nasal fiberoptic intubation	Canadian Journal of Anesthesia December 2008; 55: 12	P. Schoettker et Al.	University Hospital CHUV, Lausanne,	Switzerland

## CS#2

### **Laryngoscopy vs. Optical Stylet vs. Optical Laryngoscope (Airtraq) for Extubation Evaluation.**

Anesthesiology 2006; 105: A823. T.C. Mort, M.D. Hartford Hospital, USA

Evaluation of the difficult airway before extubation is valuable due to altered anatomy or limitations that may hinder the reintubation process.

The Shikani scope improved the ability to observe the otherwise hidden periglottic structures due to a limited “line of sight”. However, **the Airtraq offered a wide angle (panoramic) view of the periglottic structure regardless of the extent of swelling or edema or any limitation of a restricted “line of sight”.**

In this small data collection, **the Airtraq performed extremely well compared to standard laryngoscopy and an optical stylet.**

	Grade I view	Grade II View	Grade III view	Grade IV view
DL alone	1	2	2	10
DL-Shikani	9	4	2	0
Airtraq	15	0	0	0



# CS #7

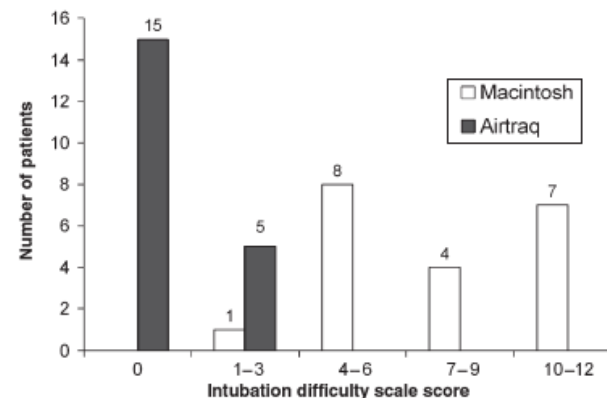
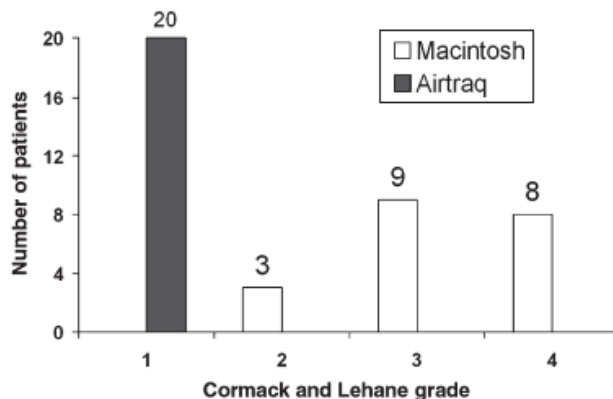
## Evaluation of the Airtraq and Macintosh laryngoscopes in patients at increased risk for difficult tracheal intubation\*

Anaesthesia, 2008, 63, pages 182–188. Maharaj CH et Al. Univ. Of Ireland, Galway

**Forty consenting patients**, who were deemed to possess at least three characteristics indicating an **increased risk for difficulty** in tracheal intubation, were randomly assigned to undergo tracheal intubation using a Macintosh (n = 20) or Airtraq (n = 20) laryngoscope.

**Four patients were not successfully intubated with the Macintosh laryngoscope, but were intubated successfully with the Airtraq.** The Airtraq reduced the duration of intubation attempts (mean (SD); 13.4 (6.3) vs 47.7 (8.5) s), the need for additional manoeuvres, and the intubation difficulty score (0.4 (0.8) vs 7.7 (3.0)).

Tracheal intubation with the Airtraq also **reduced the degree of haemodynamic stimulation and minor trauma** compared to the Macintosh laryngoscope.



## CS#8

### **The Airtraq Optical Laryngoscope: Experiences with a New Disposable Device for Orotracheal Intubation**

Anaesthesia, 2008, 63, pages 1387–1391

K. Krasser, Empress Elisabeth Hospital of the City of Vienna

Seven staff anaesthetists and two residents were novice users of the AOL. They first received formal hands-on training, and performed AOL-assisted laryngoscopy and tracheal intubation attempts on **100 patients**. Grades 1 to 5 at CLV were obtained in 36, 26, 16, 10, and 2 patients, respectively.

The success rate of AOL-assisted tracheal intubation at the **first attempt was 98%** with laryngeal views of grade 1 in all of these patients. Two patients required a second attempt, the causes were failed identification of anatomical structures and failed TT advancement during laryngeal passage. The laryngeal views obtained with the AOL during the second attempt were grade 1 in both patients. **In all patients, AOL-assisted tracheal intubation was successful (after a maximum of two attempts).**

**Following formal instruction, success of tracheal intubation with the AOL performed by novice users was not affected by CLV. The AOL proved to be uniquely useful for routine and difficult laryngoscopy and tracheal intubation.**

# CS#13

## **Success of Orotracheal Intubation with the Airtraq Optical Laryngoscope in Patients with Difficult Conventional Laryngoscopy.**

Internet Journal of Airway Management Volume 5 (January 2008 to December 2009).

Zadrobilek E.

**312 patients** for elective **thyroid surgical procedures** with various conventional laryngoscopic views. **Further 20 patients** with difficult conventional laryngoscopy (CL) also for elective thyroid surgery attempted by using the AOL were additionally included in this clinical review.

In the 332 patients evaluated, **grade 1 to 5 at CL was obtained in 111, 90, 61, 68, and 2 patients, respectively.** The overall success rate of AOL-assisted tracheal intubation at the **first attempt was 98 percent; in all patients, tracheal intubation was successful after a maximum of two attempts.**

**In the 70 patients with difficult CL (grade 4 or 5), the success rate of AOL-assisted tracheal intubation at the first attempt was 94 percent (66/70 patients).** The causes of primary failures of tracheal intubation were failed identification of anatomical structures (in one patient) and failed tracheal tube (TT) advancement during laryngeal passage (in 3 patients). Visualization of the entire laryngeal aperture was finally obtained in all patients; downsized TTs for atraumatic tracheal intubation were required in 2 patients.

# CS#26

## **An Investigation into Usefulness of Direct Optical Laryngoscope in Patients with Difficult Airways**

ASA 2009 Abstract

Neal Samuels, F.R.C.A., St. Bartholomews' Hospital, West Smithfield, London, United Kingdom

In patients with Cormack-Lehane scores 1 and 2 (n=26) there was no significant difference in laryngoscopy view between either of the laryngoscopic technique ( $p>0.05$ ). **In contrast in patients with Cormack-Lehane 3 or 4 view (n=16) the optical laryngoscopy demonstrated a statistical significant improvement in the laryngoscopy view ( $p<0.001$ ).**

**These results suggest that the Airtraq laryngoscope may have a role in the management of known (Cormack-Lehane 3 or 4 view) or predicted difficult airways (Mallampati 3 or 4) but does not improve on conventional McIntosh Blade laryngoscopy for routine airway visualisation (Grade 1 or 2 Cormack-Lehane).**

# CR#5

## **The Airtraq as a rescue airway device following failed direct laryngoscopy: a case series.**

Anaesthesia, 2007, 62, 598–601. Maharaj CH et Al. Univ. Of Ireland, Galway

This case series details the successful use of the Airtraq in seven such cases, **all of whom were intubated on the first attempt with this new device.**

In summary, this case series demonstrates that the Airtraq offers **an alternate approach to securing the difficult airway where attempts to do so by conventional direct laryngoscopy have failed.**

**Table 2** Data regarding attempts at tracheal intubation with the Macintosh laryngoscope.

	Number of intubation attempts	Number of optimisation manoeuvres	C-L view	Lowest $S_{aO_2}$ ; %	IDS	VAS
Case 1	3	2	IV	96	11	10
Case 2	3	3	IV	99	12	10
Case 3	4	3	IV	85	12	10
Case 4	2	2	IV	99	11	10
Case 5	3	3	IV	97	10	10
Case 6	3	2	IV	94	10	10
Case 7	3	3	IV	95	11	10

**Table 3** Data regarding attempts at tracheal intubation with the Airtraq laryngoscope.

	Number of intubation attempts	Duration of attempt(s)	Number of optimisation manoeuvres	C-L view	Lowest $S_{aO_2}$ ; %	IDS	VAS
Case 1	1	15	0	I	100	0	2
Case 2	1	10	0	I	99	0	2
Case 3	1	7	0	I	99	0	0
Case 4	1	20	0	I	99	1	2
Case 5	1	13	0	I	98	0	0
Case 6	1	9	0	I	100	0	0
Case 7	1	22	0	I	99	1	3

# CR#11

## Use of the Airtraq as the primary technique to manage anticipated difficult airway: a report of three cases

Journal of Clinical Anesthesia (2008) 20 – 474-477

G. Savoldelli MD Université de Genève

**Three patients with failed Intubation after three attempts with different blades. In all ett was easily placed at the first attempt.**

We argue that in this situation the **Airtraq may be a safe and effective primary technique to secure the airway**. However, we would not recommend this alternative in patients with predictors of difficult ventilations, if a supraglottic device cannot be use (limited mouth opening), in those patients at high risk of aspiration, if an apneic period cannot be tolerated, or in patients with gross deformities of the upper airway.

	BMI	TDM	IID	MP	MI CL	AT CL	Time to view	Time to cuff inflation
	(kg/m <sup>2</sup> )	(cm)	(cm)		view	view	(s)	(sec)
Case 1	26.4	6	4.0	II	IV	I	12	16
Case 2	29.7	5	4.5	III	III	I	15	19
Case 3	21	6	3.0	III	III	I	9	14

# CR#14

## **Use of the Airtraq® with a fiberoptic bronchoscope in a difficult intubation outside the operating room**

*CAN J ANESTH 55: www.cja-jca.org August, 2008*

Adrian A. Matic md, University of Wisconsin Hospital

A comatose 60-yr-old male, with extensive radiation therapy to the neck, required urgent tracheal intubation for respiratory failure (pneumonia). Airway examination revealed hardened neck structures, a limited mouth opening, a fixed mandible, the neck in flexion, and a reduced thyromental distance. **Two successful FOB attempts, were followed by the inability to slide either an 8.0-mm or a 7.0-mm endotracheal tube past the oropharynx.**

**Using the rotational insertion technique, a small Airtraq®, loaded with a 7.5-mm ETT, was passed through the limited mouth opening.** The glottis was fully visualized (“Cormack and Lehane grade 1 view”) in the left upper corner of the viewfinder. However, the hardened pharyngeal tissue did not allow any Airtraq® maneuvering of the glottis to the centre of the viewfinder for an optimal intubation attempt. Similarly, exterior laryngeal manipulation was ineffective.

**With the Airtraq® in situ, the pediatric FOB was advanced through the ETT.** The vocal cords were easily identified, and the ETT was advanced under direct visualization

## CR#18

### **Use of the Airtraq® in the difficult airway**

European Journal of Anaesthesiology 24: 720–732.

P. N. R. Ford; Royal Devon and Exeter Hospital Exeter, UK

C. Hamer, S. Medakkar; Torbay Hospital Torquay, UK

The first case was an anxious 59-yr-old male who was to undergo a total laryngectomy for cancer of the larynx. A Grade 4 view was confirmed at direct laryngoscopy using a Macintosh laryngoscope. The Airtraq® was subsequently used providing Grade 1 views of the glottis and easy passage of an endotracheal tube.

The second case was a 42-yr-old female. A Grade 3 view of the glottis was achieved at direct laryngoscopy using the Macintosh laryngoscope. When the Airtraq® was employed, a Grade 1 view of the glottis was observed and endotracheal intubation allowed to proceed uneventfully.

**The Airtraq® is cheap and extremely easy to use and we believe it should be included in the anaesthetist's armamentarium for the difficult airway.**



## CR#19

### **Use of the nasotracheal Airtraq® to assist difficult nasal fiberoptic intubation**

Canadian Journal of Anesthesia December 2008; 55: 12

P. Schoettker et Al. University Hospital CHUV, Lausanne, Switzerland

A 40-yr-old 85-kg man, was wearing a custom-made moulded **thoracocervical rigid collar due to an unstable C2 fracture**, and a Mallampati grade IV with a mouth opening of 15 mm.

Nasotracheal fiberoptic intubation with a 6.5-mm nasotracheal tube was attempted and unsuccessful due to copious bloody secretions and a collapsed orotracheal pathway.

Airtraq® was introduced through the patient's mouth while fibrescopy was still in progress. At this point, the epiglottis and vocal cords were easily visualized. The nasotracheal Airtraq® operator gave verbal directions (up, down, left, right, forward, and back) for the fibrescopy, and tracheal intubation was achieved.

**The successful completion of this case, in the face of bleeding from nasal mucosa and a limited mouth opening due to the presence of a cervical collar, illustrates a potential role for the nasotracheal Airtraq® device in a difficult nasotracheal intubation under general anesthesia.**

### 3. Obese & Obstetrics Patients

CLINICAL STUDIES					
Ref	Title	Published	Performed By	Hospital	Country
CS#5	A comparison of two techniques for inserting the Airtraq™ laryngoscope in morbidly obese patients.	Anaesthesia, 2007, 62, pages 774–777.	G. Dhonneur	Jean Verdier Public University Hospital of Paris	France
CS#12	Tracheal intubation of morbidly obese patients: a randomized trial comparing performance of Macintosh and Airtraq laryngoscopes.	British Journal of Anaesthesia 100 (2): 263–8 (2008)	S. K. Ndoko et Al.	Jean Verdier Public University Hospital of Paris	France
CS#17	Video-Assisted Versus Conventional Tracheal Intubation in Morbidly Obese Patients	Obesse Surgery (2009) 19:1096–1101	G. Dhonneur	Jean Verdier University Hospital of Paris	France
CS#27	Comparison of the AirTraq optical and the standard Macintosh laryngoscope for endotracheal intubation in obese patients	Anaesthesiology Intensive Therapy	Tomasz Gaszynski	Katedra Anestezjologii Terapii UM wLodzi	Poland

CASE REPORTS					
Ref	Title	Published	Performed By	Hospital	Country
CR#1	Tracheal Intubation Using the Airtraq_ in Morbid Obese Patients Tracheal Intubation Undergoing Emergency Cesarean Delivery.	Anesthesiology 2007; 106:629–30	G. Dhonneur	Jean Verdier Public University Hospital of Paris	France
CR#12	Awake Intubation with Airtraq Laryngoscope in a Morbidly Obese Patient.		Thida Uakritdathikarn MD	Prince of Songkla University	Thailand
CR#27	Awake Intubation with Airtraq® Laringoscope in morbidly obese patient with difficult airway	DAS Meeting 2009, Scotland	J. Estilita, J. Brasil, M. Salles-Baptista	C. Hospitalar do Barlavento Algarvio, Portimão,	Portugal

# CS#5

## **A comparison of two techniques for inserting the Airtraq laryngoscope in morbidly obese patients**

Anaesthesia, 2007, 62, pages 774–777.

G. Dhonneur. Jean Verdier Public University Hospital of Paris

For the reverse manoeuvre the laryngoscope is inserted 180° opposite to that recommended, and once in place rotated into the conventional pharyngeal position.

The reverse manoeuvre did not influence tracheal intubation characteristics in the group of lean patients. In the group of morbidly obese patients, the standard technique of insertion was not satisfactory in 20% of cases and the reverse manoeuvre facilitated, speeded and secured tracheal intubation.

**In conclusion, we have demonstrated that the reverse manoeuvre of inserting the Airtraq laryngoscope was effective in facilitating tracheal intubation, shortening the duration of the procedure and reducing the risk of upper airway trauma in morbidly obese patients.**

# CS#12

## **Tracheal intubation of morbidly obese patients: a randomized trial comparing performance of Macintosh and Airtraq**

British Journal of Anaesthesia 100 (2): 263–8 (2008)

S. K. Ndoko et Al. Jean Verdier Public University Hospital of Paris

**One hundred and six** consecutive ASA I–III morbidly obese patients undergoing surgery were randomized to intubation with the Macintosh laryngoscope or the Airtraq laryngoscope.

**In the Airtraq group, tracheal intubation was successfully carried out in all patients within 120 s. In the Macintosh laryngoscope group, six patients required intubation with the Airtraq laryngoscope.**

The mean (SD) time taken for tracheal intubation was 24 (16) and 56 (23) s, respectively, with the Airtraq and Macintosh laryngoscopes, (P,0.001). SpO<sub>2</sub> was better maintained in the Airtraq group than in the Macintosh laryngoscope group with one and nine patients, respectively, demonstrating drops of SpO<sub>2</sub> to 92% or less (P,0.05).

**Conclusions.** In this study, the Airtraq laryngoscope shortened the duration of tracheal intubation and prevented reductions in arterial oxygen saturation in morbidly obese patients.

# CS#17

## **Video-Assisted vs. Conventional Tracheal Intubation in Morbidly Obese Patients**

Obesse Surgery (2009) 19:1096–1101

G. Dhonneur, Jean Verdier University Hospital of Paris, France

318 morbidly obese patients scheduled for elective morbid obesity surgery received tracheal intubation with the LMA CTrach™, the Airtraq™ or Macintosh laryngoscope.

Duration of apnea, time to tracheal intubation, and oxygenation quality during airway management were compared between the LMA CTrach™ and the laryngoscope groups.

Our study demonstrated that, as compared to conventional direct laryngoscopy,

**visualization technology installed on the LMA CTrach™ and Airtraq™ laryngoscope augmented the ease of tracheal intubation, improved arterial oxygenation during airway management, and thus increased the safety of anesthesia in morbidly obese patients.**

Defining the respective place of the LMA CTrach™ and the Airtraq™ laryngoscope in a pre-defined algorithm in case of difficult airway [13] is of major interest for daily clinical practice of anesthesia. **Based on our clinical experience in morbidly obese patients, we now recommend the Airtraq™ laryngoscope as a plan B after 2 min of failed tracheal intubation attempt with the Macintosh laryngoscope.** The LMA CTrach™ is proposed as a plan B in case of difficult or unstable facemask ventilation during difficult tracheal intubation attempts with the Macintosh laryngoscope.

# CS#27

## **A comparison of the AirTraq optical and the standard Macintosh laryngoscope for endotracheal intubation in obese patients**

Anaesthesiology Intensive Therapy, 2009,XLI,3; 116-119

Tomasz Gaszynski , Poland

The study was performed in 68 patients; the AirTraq group consisted of 36 and the Macintosh group of 32 patients. BMI values were  $43.4 \pm 6.8$  kg m<sup>-2</sup> and  $43.3 \pm 5.5$  kg m<sup>-2</sup>, respectively. Demographic characteristics of the two groups were comparable.

The intubation time using the AirTraq optical laryngoscope was  $29 \pm 11$  sec and was significantly shorter compared to the Macintosh group –  $49 \pm 27$  sec. The number of additional manoeuvres required for improving visualization of the laryngeal aperture or insertion of the endotracheal tube was over twice lower for the AirTraq device (19% vs 50%). In the Macintosh group, guide-wires were necessary in 14 cases and changes of the blade size (to larger) in two cases. There were no traumatic complications following endotracheal intubation observed in either group.

The AirTraq optical laryngoscope enables faster and potentially less traumatic endotracheal intubation in obese patients compared to classical Macintosh laryngoscopy.

# CR#1

## **Tracheal Intubation Using the Airtraq in Morbid Obese Patients Undergoing Emergency Cesarean Delivery**

Anesthesiology 2007; 106:629–30

G. Dhonneur. Jean Verdier Public University Hospital of Paris

Two cases of rapid tracheal intubation with the Airtraq after failed direct laryngoscopy in morbidly obese patients undergoing emergency cesarean delivery.

Two validated airway devices allow visualization of the glottis without alignment of oral and pharyngeal axes: **LMA CTrach and the Airtraq** Laryngoscope (AL).

LMA CTrach, mean time to securing the airway was almost 3 min.

**Airtraq in association with rapid sequence induction resulted in a shorter delay (<1 min in most cases).**

We are now considering placing **the Airtraq as a primary airway management device in the case of emergency cesarean delivery** in women showing predictive difficult airway factors at labor or operating room clinical evaluation.

# CR#12

## **Awake Intubation with Airtraq in a Morbidly Obese Patient**

Thida Uakritdathikarn MD, MSc\*, Prince of Songkla University, Thailand

A 54-year-old Thai female, 86 kg weight and 150 cm height (**BMI 38 kg/m<sup>2</sup>**). Symptom of **gastroesophageal reflux** (GER). Mallampati class IV, interincisor gap and thyromental distance were 3 cm and 6 cm, respectively. **Limitation of head extension** was due to occipital fat pad. **Awake intubation** was suggested

The patient was preoxygenated while 50 µg of fentanyl was slowly given intravenously for sedation. Oropharynx and supraglottic area were sprayed with 10% lidocaine topically with the assistance of the McCoy laryngoscope blade. Moreover, 3 ml of 4% lidocaine was injected transtracheally through the cricothyroid membrane for laryngeal anesthesia.

The **Cormack and Lehane glottic view** showed **grade IV** when McCoy laryngoscope blade was applied.

After slight rotation of the **Airtraq**, the **glottic view** showed **grade I** and the **endotracheal tube** could be passed through the vocal cords easily.



## CR#27

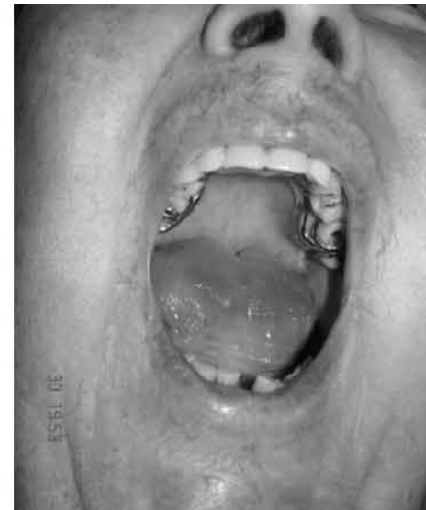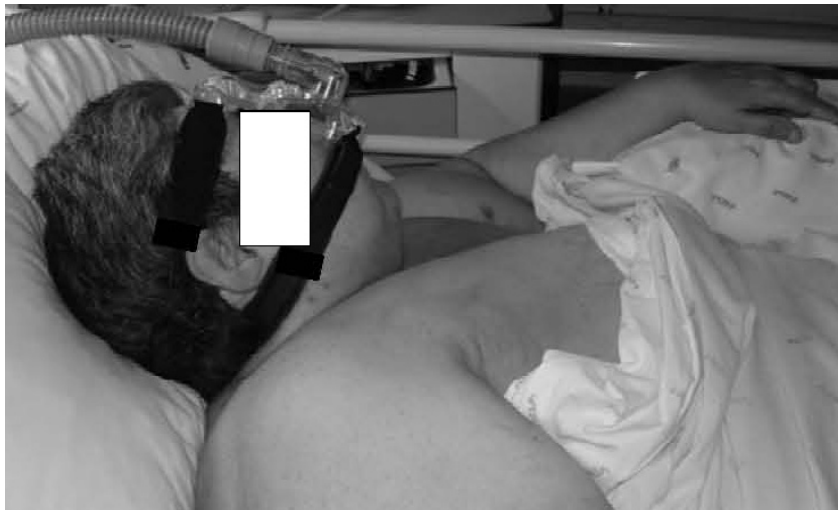### **Awake Intubation with Airtraq® Laryngoscope in morbidly obese patient with difficult airway**

J. Estilita, J. Brasil, M. Salles-Baptista, *Centro Hospitalar do Barlavento Algarvio, Portimão, Portugal*  
DAS Meeting 2009, Scotland

A 58-year-old morbidly obese (BMI 47,6 kg/m<sup>2</sup>) female patient was scheduled for an ovarian tumor staging under general anesthesia. She had sleep obstructive apnea with need for 24h BiPAP ventilation and an extensive left pleural effusion that limited the supine position.

The preoperative airway assessment predicted difficult ventilation and intubation (Figs. 1 and 2). An awake intubation using a size 3 (blue) Airtraq under light sedation and topical airway anesthesia was attempted.

Indirect laryngoscopy with Airtraq resulted in grade I C-L views. Oxygen saturation was maintained above 95%. The patient was successfully intubated at the first attempt with an 8,5 cuffed endotracheal tube, under 15 seconds. Intraoperative period and extubation were uneventful.



## 4. Awake Patients

CLINICAL STUDIES					
Ref	Title	Published	Performed By	Hospital	Country
CS#23	Airway topicalization during tracheal intubation using the Airtraq in anesthetized patients	Can J Anesth/J Can Anesth (2009) 56:994–995 DOI 10.1007/s12630-009-9187-6	F. S. Xue, MD	Chinese Academy of Medical Sciences and Peking Union	China

LETTERS TO THE EDITOR					
LE#7	Airway topical anaesthesia and awake tracheal intubation using the Airtraq® laryngoscope alone	ACTA Anaesthesiol Scand 2009; 53: 964–967	FU S. Xue, MD	Chinese Academy of Medical Sciences, Beijing	China

## 4. Awake Patients

CASE REPORTS					
Ref	Title	Published	Performed By	Hospital	Country
CR#6	Airtraq for Awake Traqueal Intubation	Anaesthesia, 2007, 62, pages 744–755	A. Suzuki, J. Henderson	Gartnavel General Hospital Glasgow	UK
CR#12	Awake Intubation with Airtraq Laryngoscope in a Morbidly Obese Patient.		Thida Uakritdathikarn MD	Prince of Songkla University	Thailand
CR#16	Awake intubation with Airtraq laryngoscope in patients with anticipated difficult airway.	European Journal of Anaesthesiology 2008; 25 (Suppl 44)	A. Gloria	Hospital Sao Joao, Porto,	Portugal
CR#17	Use of the Airtraq® as a rescue airway device following failed awake flexible fiberoptic nasotracheal intubation of a patient with severe microsomia	Korean J. Anesthesiol 2008; 55: 353~57	Jae Gyok Song, M.D.	Dankook University, Cheonan,	Korea
CR#22	Airway topical anesthesia using the Airtraq in patients with difficult airways	Can J Anesth/J Can Anesth DOI 10.1007/s12630-009-9147-1	Fu S. Xue, MD	Chinese Academy of Medical Sciences, Beijing	China
CR#23	Awake tracheal intubation using the Airtraq : a case series	Acta Anaesthesiol Scand 2009; 53: 964–967	V. K. Dimitriou	'G Genimmatas' General Hospital of Athens	Greece
CR#27	Awake Intubation with Airtraq® Laringoscope in morbidly obese patient with difficult airway	DAS Meeting 2009, Scotland	J. Estilita, J. Brasil, M. Salles-Baptista	C. Hospitalar do Barlavento Algarvio, Portimão,	Portugal

# CS#23

## **Airway topicalization during tracheal intubation using the Airtraq in anesthetized patients**

Can J Anesth/J Can Anesth (2009) 56:994–995 DOI 10.1007/s12630-009-9187-6

*Fu S.Xue,MD* Chinese Academy of Medical Sciences and Peking Union Medical College, Beijing

The MADett™ is a new device designed to spray medications directly into the lungs via the ETT without interrupting ventilation in the intubating patients. Recently, we have successfully combined the Airtraq laryngoscope and the MADett™ to provide topicalization of the glottis and trachea during tracheal intubation in anesthetized patients, **30 patients.**

**In all patients, a Cormack-Lehane grade 1 glottic view was obtained by the Airtraq.**

In 29 patients, airway topicalization and tracheal intubation were completed successfully on the first attempt without extra manoeuvres. **In one patient, however, the initial attempt to guide the ETT tip towards the glottis failed because the ETT took a posterior direction below the glottis. After the Airtraq\_ laryngoscope was withdrawn 2 cm away from the glottis and lifted upwards, the ETT tip was directed towards the glottis and airway topicalization and tracheal intubation were then accomplished.**

## LE#7

### **Airway topical anaesthesia and awake tracheal intubation using the Airtraq® Laryngoscope alone**

Acta Anaesthesiol Scand 2009; 53: 964–7.

Chinese academy of Medical sciences and Peking union medical College. Fu Shan Xue

We find that after topical anaesthesia of the mouth and pharynx with the atomized lidocaine, and sedation management with intravenous fentanyl and midazolam, the patient may well tolerate the insertion of the Airtraq and the superior laryngeal vision can be obtained by the Airtraq. We prefer to use aMADgic® laryngotracheal atomizer (MAD-LTA) to provide topical anaesthesia of the larynx, the infraglottic area and the trachea under direct vision on the viewfinder of the Airtraq.

When the glottis is in the centre of the viewfinder, the curved applicator portion of a MAD-LTA is advanced through the lateral channel of the AL and its tip is in order positioned immediately superior to the glottis and the bilateral pyriform recess under direct vision on the viewfinder.

Our experience suggests that this technique is non-invasive and does not carry the potential risk of airway damage. Also, it is easy to perform and can provide excellent topical anesthesia of the airway.

# CR#6

## **Airtraq for awake tracheal intubation**

Anaesthesia, 2007, 62, pages 746-747.

Suzuki, J. Henderson. Gartnavel General Hospital Glasgow

**An initial attempt with the conventional Macintosh blade was unsuccessful** because laryngoscopy was difficult and poorly tolerated **due to an active gag reflex**. An attempt was next made with the Airtraq with some modification of the device. The tracheal tube was placed in the side channel of the **Airtraq and connected to the respiratory circuit** via a Bodai Suction Safe swivel Y-connector . Oxygen at 10 l.min was administered to prevent desaturation of the patient.

Excessive **saliva in the oropharynx was removed under vision via a 14Fr suction catheter inserted through the tracheal tube** via the Bodai connector. Visualisation of the patient's vocal cords was achieved easily, the percentage of glottic opening (POGO) score [2] being 70%. After additional topical anaesthesia was applied to the vocal cords with a tracheal spray tube, the patient's trachea was intubated uneventfully at the first attempt.

We conclude that **the Airtraq with the modifications described above can be a useful and well-tolerated device in management of patients who require awake tracheal intubation.**

# CR#12

## **Awake Intubation with Airtraq in a Morbidly Obese Patient**

Thida Uakritdathikarn MD, MSc\*, Prince of Songkla University, Thailand

A 54-year-old Thai female, 86 kg weight and 150 cm height (**BMI 38 kg/m<sup>2</sup>**). Symptom of **gastroesophageal reflux** (GER). Mallampati class IV, interincisor gap and thyromental distance were 3 cm and 6 cm, respectively. **Limitation of head extension** was due to occipital fat pad. **Awake intubation** was suggested

The patient was preoxygenated while 50 µg of fentanyl was slowly given intravenously for sedation. Oropharynx and supraglottic area were sprayed with 10% lidocaine topically with the assistance of the McCoy laryngoscope blade. Moreover, 3 ml of 4% lidocaine was injected transtracheally through the cricothyroid membrane for laryngeal anesthesia.

The **Cormack and Lehane glottic view** showed **grade IV** when McCoy laryngoscope blade was applied.

After slight rotation of the **Airtraq**, the **glottic view** showed **grade I** and the **endotracheal tube** could be passed through the vocal cords easily.

## CR#16

### **Awake intubation with Airtraq laryngoscope in patients with anticipated difficult airway**

European Journal of Anaesthesiology 2008; 25 (Suppl 44)

A. Gloria et Al. Hospital Sao Joao, Porto, Portugal

Indirect laryngoscopy with Airtraq resulted in grade I C-L views. Oxygen saturation was maintained above 95%. **All the patients were successfully intubated with the Airtraq at first attempt.**

In this case series the Airtraq Laryngoscope proved to be an effective intubation device and can be considered as a valid option in an anticipated difficult airway situation (2). **For the patients it was safe and comfortable to use the Airtraq while they were awake and breathing spontaneously.**

	Age	Gender	Predictors of difficult airway	Mallampati score	Surgery
Case 1	66	Male	Obesity; Protruding upper teeth; Short neck; Limited cervical extension; Grade IV Cormack and Lehane view	4	Hypofisis adenoma resection
Case 2	52	Female	Micrognathia; Inter-incisors distance =1,5 cm	4	Laparoscopic cholecistectomy
Case 3	51	Male	Cervical immobilization; Obesity; Short neck; Respiratory insufficiency; Tetraplegy	4	Post-operative laminectomy
Case 4	56	Male	Reumathoid arthritis; Cifoscoliosis; Short neck; Central obesity	4	Exploratory laparotomy
Case 5	60	Male	Retrofaryngeal abcess; Limited cervical extension; Grade IV Cormack and Lehane view	3	Abcess drainage
Case 6	59	Male	Obesity; Short neck	4	Shoulder surgery



## CR#17

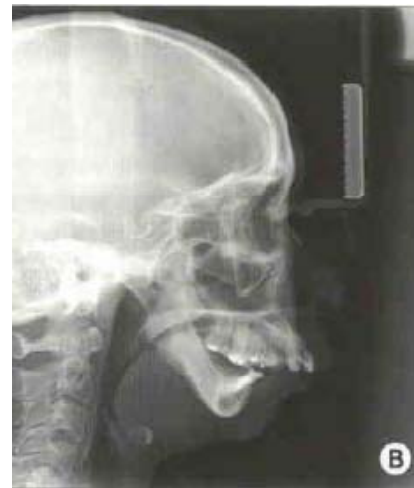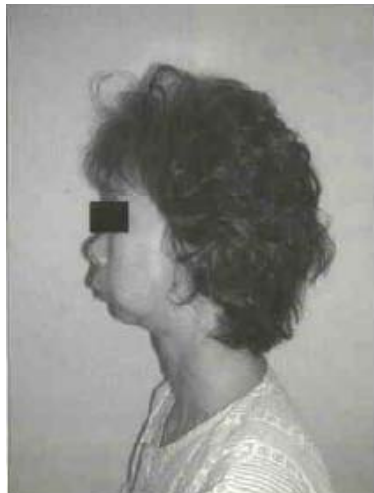### **Use of the Airtraq® as a rescue airway device following failed awake flexible fiberoptic nasotracheal intubation of a patient with severe microsomia**

Korean J. Anesthesiol 2008; 55: 353~57

Jae Gyok Song, M.D. Dankook University, Cheonan, Korea

We attempted awake fiberoptic nasotracheal intubation following topical anesthesia with 4% lidocaine spray three times to induce general anesthesia for distraction osteogenesis of mandibular bone. However, due to a shallow pharyngeal cavity and cranially displaced larynx, we failed to locate the larynx each time and were therefore not able to intubate the patient.

**Awake orotracheal intubation using the AOL allowed us to easily intubate the patient. Therefore, we recommend that the AOL be used as a rescue airway device for intubation of difficult airways.**



## CR#22

### **Airway topical anesthesia using the Airtraq in patients with difficult airways**

Can J Anesth/J Can Anesthesia, DOI 10.1007/s12630-009-9147-1

Fu S. Xue, MD, Chinese Academy of Medical Sciences, Beijing

Based on our preliminary experience in **15 adult patients with known difficult airways** (due to micrognathia, a short neck, and/or limited head and neck movement), several advantages appear to exist with this technique.

First, because the Airtraq laryngoscope has a wide lateral channel, the applicator portion of the MAD-LTA can well be adapted to the curved blade of the Airtraq laryngoscope. Also, the tip of the MAD-LTA can be directed easily towards the different targeted airway structures by adjusting its distal position under the superior vision of the airway provided by the Airtraq laryngoscope.

Second, this approach can provide **excellent airway topical anesthesia for awake orotracheal intubation**, because the MADLTA can provide effective atomized lidocaine solution to the airway mucosa.

Third, this technique **is well tolerated by the awake, sedated patient, possibly due to less stimulation of the oropharyngolaryngeal structures during the laryngeal exposure using the Airtraq** laryngoscope, as it does not require a 'line of sight' to visualize the airway anatomy.

Fourth, this **technique is easy to perform**.

Therefore, we believe this technique can provide a **favorable alternative to a fiberoptic technique** for the management of difficult airways.

## CR#23

### **Awake tracheal intubation using the Airtraq : a case series**

Acta Anaesthesiol Scand 2009; 53: 964–967

V. K. Dimitriou, 'G Genimatas' General Hospital of Athens

We report **four cases of awake tracheal intubation with the Airtraq in patients with anticipated difficult airway**. Cervical extension was not possible at all in the patient with ankylosing spondylitis and was very limited in the other cases.

Because forceful elevation of the epiglottis is not required, it seems that the Airtraq needs less force and therefore may be suitable for awake tracheal intubation. Additionally, the built in **anti-fog** technology in the lens at the distal end, makes the Airtraq suitable for **patients breathing spontaneously**. When using the AL, the **tracheal tube does not obstruct the endoscopic view of the vocal cords during intubation**,

The transtracheal injection of local anaesthetic resulted in **no discomfort** during insertion of the tube into the trachea. We did not administer sedation to the patients with the extensive submandibular abscess or haematoma.

The preparation for the topical anaesthesia required about 5min and the intubation procedure about 20–25 s. Thus, the suggested technique may be used even in cases of relative emergency situations.

This case series demonstrates that the Airtraq can be used **effectively to accomplish an awake intubation in patients with a suspected or known difficult airway and may be a useful alternative** where other methods have failed or are not available.

## CR#27

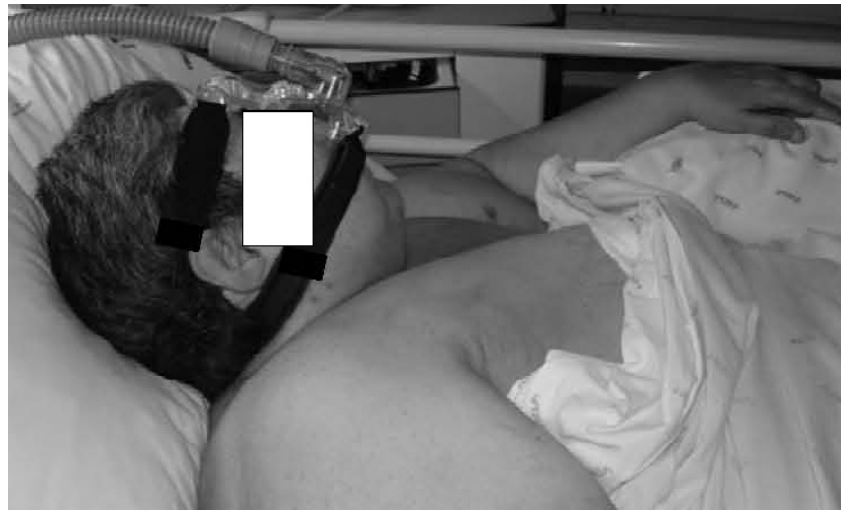### **Awake Intubation with Airtraq® Laryngoscope in morbidly obese patient with difficult airway**

J. Estilita, J. Brasil, M. Salles-Baptista, *Centro Hospitalar do Barlavento Algarvio, Portimão, Portugal*  
DAS Meeting 2009, Scotland

A 58-year-old morbidly obese (BMI 47,6 kg/m<sup>2</sup>) female patient was scheduled for an ovarian tumor staging under general anesthesia. She had sleep obstructive apnea with need for 24h BiPAP ventilation and an extensive left pleural effusion that limited the supine position.

The preoperative airway assessment predicted difficult ventilation and intubation (Figs. 1 and 2). An awake intubation using a size 3 (blue) Airtraq under light sedation and topical airway anesthesia was attempted.

Indirect laryngoscopy with Airtraq resulted in grade I C-L views. Oxygen saturation was maintained above 95%. The patient was successfully intubated at the first attempt with an 8,5 cuffed endotracheal tube, under 15 seconds. Intraoperative period and extubation were uneventful.



## 5. Trauma, Bleeding & C-Spine Immobilization

CLINICAL STUDIES					
Ref	Title	Published	Performed By	Hospital	Country
CS#2	Laryngoscopy vs. Optical Stylet vs. Optical Laryngoscope (Airtraq) for Extubation Evaluation.	American Society of Anesthesiologists October 14-18, 2006	T.C. Mort, M.D.	Hartford Hospital	USA
CS#1	Endotracheal Intubation in Patients with Cervical Spine Immobilization. A Comparison of Macintosh and Airtraq Laryngoscopes.	Anesthesiology 2007; 107:53-9	Maharaj CH et Al.	Univ. Of Ireland, Galway	Ireland
CS#9	A comparison of cervical spine movement during laryngoscopy using the Airtraq or Macintosh laryngoscopes*	Anaesthesia, 2008, 63, pages 635-640	Y. Hirabayashi, MD and N.Seo, MD	Jichi Medical University	Japan
CS#10	C-Spine Movement Macintosh vs. Airtraq	Journal Watch Emergency Medicine June 13, 2008	Aaron E. Bair,MD,	Dep. of Emergency Medicine at the Univ. of California	USA
CS#11	Comparison of Cervical Spine Movement using the Airtraq versus Macintosh Blade: A Fluoroscopic Randomized Controlled Trial.	SAM Meeting 2008	Timothy P. Turkstra	University of Western Ontario	Canada.
CS#18	Tracheal intubation in patients with rigid collar immobilisation of the cervical spine: a comparison of Airtraq and CTrach devices	Anaesthesia, 2009, 64, pages 1332-1336 doi:10.1111/j.1365-2044.2009.06053	Z. I. Arslan	University of Kocaeli	Turkey

## 5. Trauma, Bleeding & C-Spine Immobilization

CASE REPORTS					
Ref	Title	Published	Performed By	Hospital	Country
CR#2	Tracheal intubation in polytraumatized patients using the Airtraq laryngoscope: First experiences of a new pre-hospital emergency service.	Revista Electrónica de Medicina Intensiva Article nº A49. Vol 6 nº 6, june 2006	Nieves de Lucas García	Samur-Protección Civil, Madrid	Spain
CR#3	Intubation using the Airtraq laryngoscope in patients with mandibular fracture.	Revista Electrónica de Medicina Intensiva". Case nº 15. Vol 6 nº 7, july 2006	Nieves de Lucas García	Samur-Protección Civil, Madrid	Spain
CR#7	Emergency use of the Airtraq laryngoscope in traumatic asphyxia: case report. .	040469Emerg. Med. J.2007;24;509-510 doi:10.1136/emi.2006	John J M Black.	John Radcliffe Hospital, Oxford	UK
CR#8	A managed case of difficult intubation with optical laryngoscope "AirTraq" . Un caso di intubazione difficile gestito con laringoscopia ottico AirTraq"	BUSNAGO SOCCORSO o.n.l.u.s	Fabio Salvatore Lioni	Associazione Volontaria Interprovinciale di Soccorso	Italy
CR#21	The Airtraq laryngoscope in severe ankylosing spondylitis	JR Army Med Corps 154 (1): 76-78	Basaranoglu G, et Al.	Vakif Gureba Education and Teaching Hospital, Istanbul,	Turkey.

## CS#2

### **Laryngoscopy vs. Optical Stylet vs. Optical Laryngoscope (Airtraq) for Extubation Evaluation.**

Anesthesiology 2006; 105: A823. T.C. Mort, M.D. Hartford Hospital, USA

Evaluation of the difficult airway before extubation is valuable due to altered anatomy or limitations that may hinder the reintubation process.

The Shikani scope improved the ability to observe the otherwise hidden periglottic structures due to a limited “line of sight”. However, **the Airtraq offered a wide angle (panoramic) view of the periglottic structure regardless of the extent of swelling or edema or any limitation of a restricted “line of sight”.**

In this small data collection, **the Airtraq performed extremely well compared to standard laryngoscopy and an optical stylet.**

	Grade I view	Grade II View	Grade III view	Grade IV view
DL alone	1	2	2	10
DL-Shikani	9	4	2	0
Airtraq	15	0	0	0

## CS#4

### **Endotracheal Intubation in Patients with Cervical Spine Immobilization** **A Comparison of Macintosh and Airtraq Laryngoscopes**

Anesthesiology 2007; 107:53–9. Maharaj CH et Al. Univ. Of Ireland, Galway

The Airtraq reduced the duration of intubation attempts (mean SD: 13.2 5.5 vs. 20.3 12.2 s), the need for additional manoeuvres, and the intubation difficulty scale score (0.1 0.5 vs. 2.7 2.5). Tracheal intubation with the Airtraq caused fewer alterations in blood pressure and heart rate.

Conclusions: **These findings demonstrate the utility of the Airtraq laryngoscope for tracheal intubation in patients with cervical spine immobilization.**

Table 3. Data for Intubation Attempts with Each Device

Parameter Assessed	Macintosh	Airtraq
Overall success rate (%)	19 (95)	20 (100)
Intubation difficulty scale score	2 (0.3)	0 (0.0)†
Duration of intubation attempt, s	20.3 ± 12.2	13.2 ± 5.4*
Lowest SpO <sub>2</sub> during intubation attempt, %	98.7 ± 1.4	99.4 ± 0.7
No. of intubation attempts (%)		
1	19 (95)	20 (100)
2	0	0
3	1 (5)	0
No. of optimization maneuvers (%)		
0	12 (60)	20 (100)*
1	5 (25)	0
≥ 2	3 (15)	0



## CS#9

### **A comparison of cervical spine movement during laryngoscopy using the Airtraq or Macintosh laryngoscopes**

Anaesthesia, 2008, 63, pages 635–640

Y. Hirabayashi, A. Fujita, N. Seo and H. Sugimoto. Jichi Medical University. Japan

**In 20 patients** requiring general anaesthesia and tracheal intubation, we measured cervical spine movement using radiography in the same patient during consecutive procedures using the two laryngoscopes.

Cervical spinal extension with the Airtraq was **29% less** than that measured during Macintosh laryngoscopy between the occiput and C4, and 44% less at the C3/C4 motion segment ( $p < 0.05$ ).

Anterior deviations of the vertebral bodies from baseline were **32%, 35%, 38% and 40% less** at the atlas, C2, C3, and C4 vertebrae, respectively, during Airtraq laryngoscopy than those measured during Macintosh laryngoscopy ( $p < 0.01$ ).

Our study demonstrated that **laryngoscopy using the Airtraq laryngoscope involves less movement of the cervical spine compared to conventional procedures using a Macintosh laryngoscope**. Thus, intubation with the aid of an Airtraq seems **more suitable than Macintosh laryngoscopy especially for those patients in whom neck extension is to be avoided**.

# CS#10

## **C-Spine Movement Macintosh vs. Airtraq**

Journal Watch Emergency Medicine June 13, 2008

Aaron E. Bair, MD, Dep. of Emergency Medicine at the Univ. of California

**Twenty adult patients** who required routine intubation for elective gynecologic surgery in the operating suite underwent laryngoscopy with both the Airtraq and Macintosh devices, in random order. Patients with a history of difficult intubation or C-spine injury were excluded. All laryngoscopies were performed by a single anesthesiologist who was skilled in both techniques.

Lateral radiographs were taken at baseline with the patient in a neutral position and during laryngoscopy when the best view of the larynx was obtained. Two radiologists reviewed the radiographs to measure the degree of vertebral body displacement.

**C-spine extension was significantly less with the Airtraq than with the Macintosh: 29% less at the occiput–C4 segment and 44% less at the C3–C4 segment.**

# CS#11

## **Cervical Spine Motion: A Fluoroscopic Comparison of the AirTraq versus the Macintosh**

Anesthesiology 2009; 111:97–101

T.P. Turkstra et Al. University of Western Ontario, London, ON, Canada

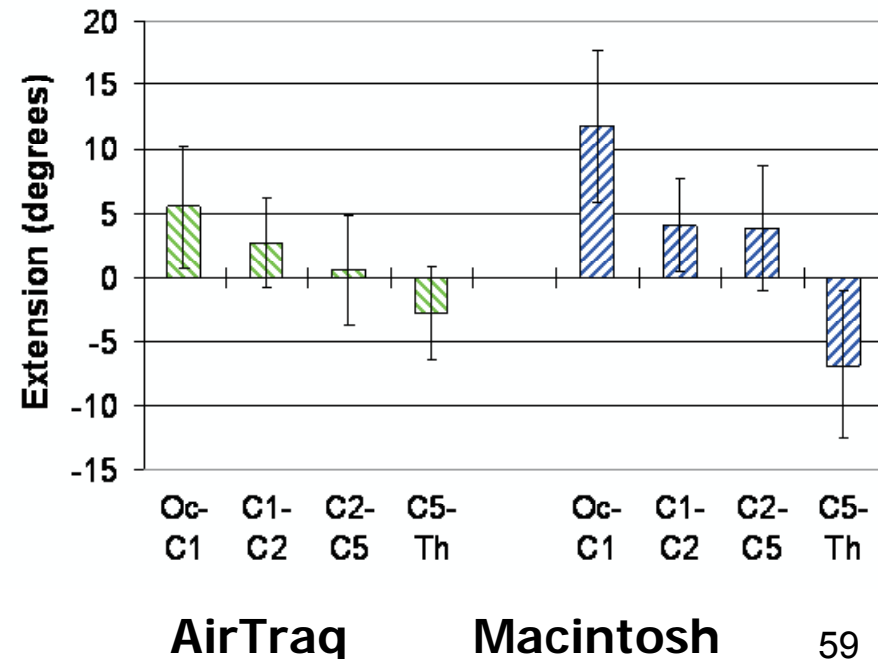
We studied 24 patients. Manual in-line stabilization was provided by an assistant.

**C-spine motion was 53%, 95%, and 60% less** during laryngoscopy with ATQ compared to the Macintosh blade at the Occiput-C1, C2-C5, and C5-Thoracic motion segments.

Improved view might be valuable in situations of suspected trauma to the larynx or vocal cords.

The AirTraq may be a useful tool to experienced users in the setting of “uncleared” C-spine patients, particularly if an injury is suspected in the Occiput-C1 or C2-C5 areas of the C-spine or below.

Data maybe more relevant to the prehospital setting, where patients with unclear C-spines could be expected more frequently.



# CS#18

## **Tracheal intubation in patients with rigid collar immobilisation of the cervical spine: a comparison of Airtraq® and LMA CTrach™**

Anaesthesia, 2009,64,pages 1332-1336 doi;10.1111/j.1365-2044.2009.06053.x

Z.L.Arslan, University of Kocaeli, Turkey

Eighty-six adult patients . After anaesthesia was induced a rigid cervical collar was applied.

The mean **time to see the glottis was shorter with Airtraq** than the CTrach (11.9 (6.8) vs 37.6(16.7)s.

The mean time taken for **tracheal intubation was also shorter with the Airtraq** than with the CTrach (25.6(13.5) and 66.3 (29.3)s, respectively. **There was less mucosal damage in the Airtraq group.**

Additional manoeuvres were required to provide an optimal view of the glottis in two patients (5%) from the Airtraq and 27 patients (63%) from the CTrach groups.

# CR#2

## **Tracheal intubation in polytraumatized patients using the Airtraq First experiences of a new pre-hospital emergency service**

REMI- Article No. A49. Vol 6 No. 6, June 2006

Nieves de Lucas García. Samur-Protección Civil, Madrid

**Case 1.** A 33 year-old male patient who had fallen from a second floor, was treated at the scene by a pre-hospital emergency service. On arrival he was unconscious, with a **Glasgow Coma Scale Score of 3** He was placed in a cervical collar, with a chin support brace, and intubated with the Airtraq in barely 15 seconds, without removing the cervical collar from its place or making any minimum significant neck movement.

**Case 2.** A 78 year-old male patient who had fallen from a height of 5 metres was treated at the scene of the accident by the pre-hospital emergency service. We suspected he could suffer **moderate craniocerebral trauma** because his rating on the Glasgow Coma Scale Score, (GCS) had dropped from 14 to 12 during the first few minutes, as well as diaphragm trauma and abdominal trauma. **In 20 seconds he was intubated using the Airtraq after he had been applied cervical collar and his head immobilized** (the manoeuvre included the visualization of the glottis by an accompanying doctor).

# CR#3

## **Intubation using the Airtraq in patients with maxillary fracture**

Intensive Care Medicine Volume 6 No. 7, July 2006.

Nieves de Lucas García. Samur-Protección Civil, Madrid

A male patient (estimated age is 65 years old), **run over by a vehicle in a speedway**. He was immediately treated on the scene by an extra hospital emergency service (The Samur in Madrid).

The patient presented a frontal trauma with a wound bleeding profusely, zygomatic bone fracture and maxillary fracture. He had a sternum fracture and an arrhythmia condition, with bilateral basal hyperventilation. We could hardly hear any bowel sounds in the abdomen and, though it was soft, it initially revealed defence in the left hemiabdomen. The electrocardiogram revealed auricular fibrillation. Vital signs: 140 lpm, 20 rpm, TA 83/65 mmHg, oxygen saturation reached 93%, with a **Glasgow Coma Score of 8**.

**After various unsuccessful intubation attempts with conventional laryngoscope we managed to intubate the patient using the Airtraq without any problems.**

# CR#7

## **Emergency use of the Airtraq laryngoscope in traumatic asphyxia: case report**

Emerg. Med. Journal 2007;24;509-510 doi:10.1136/emj.2006.040469

John J M Black. John Radcliffe Hospital, Oxford

It was used to successfully intubate a severely injured 41-year-old patient who had **sustained traumatic asphyxia after attempting suicide by hanging.**

He was **bleeding into his upper airway**, necessitating regular suctioning. The patient underwent an emergency **rapid sequence intubation** at the scene of injury, with **in-line immobilisation** and cricoid pressure while lying on the ground in bright sunlight.

**A Cormack and Lehane grade 1 view of the oedematous vocal cords was readily obtained, and successful endotracheal intubation was rapidly achieved at the first attempt.** The endotracheal tube was clearly seen to pass through the vocal cords and enter the trachea.

The Airtraq required minimal manipulation to obtain a close-up, panoramic, high-grade view of the larynx.

# CR#8

## ***A managed case of difficult intubation with "Airtraq"***

Fabio Salvatore Lioni. Associazione Volontaria Interprovinciale di Soccorso

The case regards one young Austrian woman of 20 years, who remained victim of a road accident.

On delivery patient, it was reported to us that on the scene of the accident the **intubation was impossible**, for that reason it was used a laryngeal mask. Once arrived at the hospital, after some trying, the patient has been intubated with the aid of a **fibroscope**.

After a short way, arrived at the airport, during boarding procedures of the patient, the pilot balloon of the cuff was completely deflated. It was tried to inflate again the tube but without success, while the pressure obtained with the ventilations was not sufficient to maintain adequate exchanges.

**After two unsuccessful intubation attempts** – by deeper sedation-it was positioned a laryngeal mask, while we consulted our helicopter ambulance colleagues about the solutions to adopt.

**The Anesthesiologist-Resuscitator of the helicopter ambulance uses therefore the AirTraq (aircraft's equipment) for the intubation of the patient, together with an ET tube of ID 6.5. The intubation, although with some difficulties, succeeds at the first attempt.**



## CR#21

### **Airtraq In severe ankylosing spondylitis**

JR Army Med Corps 154 (1): 76-78

Basaranoglu G, et Al. Vakif Gureba Education and Teaching Hospital, Istanbul,

We would like to report the successful use of the Airtraq as a rescue device following failed awake fibreoptic intubation in a patient with ankylosing spondylitis (AS).

A 48-yr-old male with a BMI of 32.5 and a long history of ankylosing spondylitis was admitted for elective nephrolithotomy. Physical examination revealed an immobile neck, head extension fixed at 150° and a Mallampati Class II airway. **Lateral X-Ray confirmed widespread cervical ankylosis.**

A regional anaesthetic technique was excluded due to patient choice, so an awake fibreoptic intubation was planned followed by general anaesthesia. An antisialogogue (atropine 500mcg) was given and small boluses of intravenous midazolam were titrated to response (2.5mg). Following a standard technique to topically anaesthetise the airway using lidocaine (100 mg), **fibreoptic endoscopy was attempted but the intubation was unsuccessful due to mechanical failure of the endoscope.** Anaesthesia was then induced using a bolus of propofol (1mg/kg) and an uncomplicated intubation (size 8.0mm endotracheal tube) was achieved using the Airtraq laryngoscope.

In experienced hands awake fibreoptic intubation is often the best option for securing the airway in patients with difficult airways, e.g. ankylosing spondylitis [2] though the technique does have a low failure rate. **Both the fibrescope and the Airtraq laryngoscope can provide a full indirect view of the glottis without the need for anatomical alignment [3]. However, intubation proficiency with the Airtraq can be achieved quickly and it has a shorter learning curve than fibreoptic endoscopy.**

## 6. Prehospital & Military

CLINICAL STUDIES					
Ref	Title	Published	Performed By	Hospital	Country
CS#14	Airtraq tracheal intubation by novice laryngoscopists	Emergency Medicine Journal 2009; 26; 112-113	Y. Hirabayashi, MD and N.Seo, MD	Jichi Medical University	Japan

CASE REPORTS					
Ref	Title	Published	Performed By	Hospital	Country
CR#2	Tracheal intubation in polytraumatized patients using the Airtraq laryngoscope: First experiences of a new pre-hospital emergency service.	Revista Electrónica de Medicina Intensiva Article nº A49. Vol 6 nº 6, june 2006	Nieves de Lucas García	Samur-Protección Civil, Madrid	Spain
CR#3	Intubation using the Airtraq laryngoscope in patients with mandibular fracture.	Revista Electrónica de Medicina Intensiva". Case nº 15. Vol 6 nº 7, july 2006	Nieves de Lucas García	Samur-Protección Civil, Madrid	Spain
CR#7	Emergency use of the Airtraq laryngoscope in traumatic asphyxia: case report. .	040469Emerg. Med. J.2007;24;509-510 doi:10.1136/emj.2006	John J M Black.	John Radcliffe Hospital, Oxford	UK
CR#8	A managed case of difficult intubation with optical laringoscope "AirTraq" . Un caso di intubazione difficile gestito con laringoscopio ottico AirTraq"	BUSNAGO SOCCORSO o.n.l.u.s	Fabio Salvatore Lioni	Associazione Volontaria Interprovinciale di Soccorso	Italy
CR#10	Experience with a patient having multiple gunshot wounds in combat	AANA Journal – February 2008 – Vol. 76, No. 1	CPT Peter Strube	948th Forward Surgical Team Camp Delta, Al Kut, Iraq	Iraq

## 6. Prehospital & Military

LETTERS TO THE EDITOR					
Ref	Title	Published	Performed By	Hospital	Country
LE#5	The management of difficult direct laryngoscopy and intubation in a field hospital: An alternative to fiberoptic endoscopy	JR Army Med Corps 153(3): 181-183	JL Tong	Royal Centre for Defence Medicine, Birmingham	UK
LE#6	Video Laryngoscopy in the Prehospital Setting	Prehospital and Disaster Medicine, May – June 2009, <a href="http://pdm.medicine.wisc.edu">http://pdm.medicine.wisc.edu</a>	Lars P. Bjoernsen,MD	University of Wisconsin Hospitals and Clinics	USA

## 6. Prehospital & Military

MANIKIN STUDIES					
Ref	Title	Published	Performed By	Hospital	Country
MS#4	Use of the Airtraq laryngoscope in a model of difficult intubation by prehospital providers not previously trained in laryngoscopy.	Anaesthesia, 2007, 62, pages 1061–1065	M. Woollard	Australian College of Ambulance Professionals	Australia
MS#5	Airtraq vs standard laryngoscopy by student paramedics and experienced prehospital laryngoscopists managing a model of difficult intubation*	Anaesthesia, 2008, 63, pages 26–31 doi:10.1111/j.1365-2044.	M. Woollard	Australian College of Ambulance Professionals	Australia
MS#8	A comparative study of Endotracheal Intubation by Airtraq, Glidescope ranger and Direct Laryngoscopy in a Closed Space Environment.	Annals of Emergency Medicine S113, Volume 52, No 4 October 2008.	Hampton MS	Adams BD/San Antonio Health Education Consortium	USA
MS#11	Comparison of the Airtraq® and Truview® to the Macintosh for use by Advanced Paramedics in easy and simulated difficult intubation in manikins	BMC Emergency Medicine 2009, 9:2	S. Nasim,	Galway University Hospitals, Sligo General Hospital, National University	Ireland
MS#12	Airway Management At Floor Level: A Comparison Of Tracheal Intubation Using The Macintosh And Airtraq Laryngoscopes	JR Army Med Corps 154(1): 21-25	JL Tong,	Royal Centre for Defence Medicine; Hospitals; University Hospital Birmingham,	UK
MS#13	Comparison of Use of the Airtraq with Direct Laryngoscopy by Paramedics in the Simulated Airway	Prehospital Emergency Care	T. A. Nowicki	University of Connecticut Hospital	USA

# CS#14

## **Airtraq tracheal intubation by novice laryngoscopists**

*Emerg. Med. J.* 2009;26;112-113113doi:10.1136/emj.2008.059659

Yoshihiro Hirabayashi, Norimasa Seo, Jichi Medical University, Japan

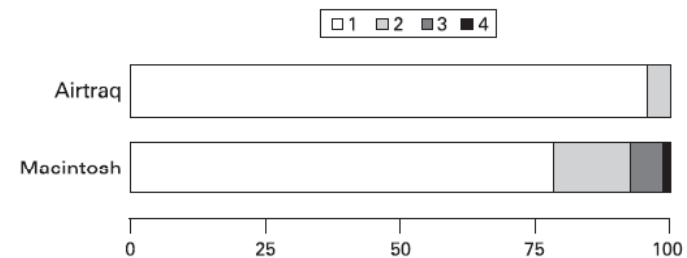
Under supervision by staff anaesthetists, **nonanaesthesia physicians** performed tracheal intubation using either the **Airtraq (n = 100)** or the Macintosh laryngoscope (n = 100).

The **time to secure the airway was shorter with the Airtraq** than with the Macintosh laryngoscope (p,0.001).

The **number of attempts until successful intubation was smaller with the Airtraq** than with the Macintosh laryngoscope (p,0.001).

**Erroneous oesophageal intubation was less with the Airtraq optical laryngoscope** than with the Macintosh laryngoscope (p,0.01).

Differences in tracheal intubation procedure using the Airtraq and Macintosh laryngoscopes by non-anaesthesia novice physicians			
	Airtraq	Macintosh	p Value
Time to intubation, in seconds (SD)*	51 (17)	67 (43)	0,001
Erroneous intubation of the oesophagus	0	10	0,01



**Figure 2** The number of attempts until successful intubation using the Airtraq and Macintosh laryngoscope by non-anaesthesia novice physicians. Mann-Whitney U test showed the significant difference between the two groups (p<0.001).

# CR#2

## **Tracheal intubation in polytraumatized patients using the Airtraq First experiences of a new pre-hospital emergency service**

REMI- Article No. A49. Vol 6 No. 6, June 2006

Nieves de Lucas García. Samur-Protección Civil, Madrid

**Case 1.** A 33 year-old male patient who had fallen from a second floor, was treated at the scene by a pre-hospital emergency service. On arrival he was unconscious, with a **Glasgow Coma Scale Score of 3** He was placed in a cervical collar, with a chin support brace, and intubated with the Airtraq in barely 15 seconds, without removing the cervical collar from its place or making any minimum significant neck movement.

**Case 2.** A 78 year-old male patient who had fallen from a height of 5 metres was treated at the scene of the accident by the pre-hospital emergency service. We suspected he could suffer **moderate craniocerebral trauma** because his rating on the Glasgow Coma Scale Score, (GCS) had dropped from 14 to 12 during the first few minutes, as well as diaphragm trauma and abdominal trauma. **In 20 seconds he was intubated using the Airtraq after he had been applied cervical collar and his head immobilized** (the manoeuvre included the visualization of the glottis by an accompanying doctor).

# CR#3

## **Intubation using the Airtraq in patients with maxillary fracture**

Intensive Care Medicine Volume 6 No. 7, July 2006.

Nieves de Lucas García. Samur-Protección Civil, Madrid

A male patient (estimated age is 65 years old), **run over by a vehicle in a speedway**. He was immediately treated on the scene by an extra hospital emergency service (The Samur in Madrid).

The patient presented a frontal trauma with a wound bleeding profusely, zygomatic bone fracture and maxillary fracture. He had a sternum fracture and an arrhythmia condition, with bilateral basal hyperventilation. We could hardly hear any bowel sounds in the abdomen and, though it was soft, it initially revealed defence in the left hemiabdomen. The electrocardiogram revealed auricular fibrillation. Vital signs: 140 lpm, 20 rpm, TA 83/65 mmHg, oxygen saturation reached 93%, with a **Glasgow Coma Score of 8**.

**After various unsuccessful intubation attempts with conventional laryngoscope we managed to intubate the patient using the Airtraq without any problems.**

# CR#7

## **Emergency use of the Airtraq laryngoscope in traumatic asphyxia: case report**

Emerg. Med. Journal 2007;24;509-510 doi:10.1136/emj.2006.040469

John J M Black. John Radcliffe Hospital, Oxford

It was used to successfully intubate a severely injured 41-year-old patient who had **sustained traumatic asphyxia after attempting suicide by hanging.**

He was **bleeding into his upper airway**, necessitating regular suctioning. The patient underwent an emergency **rapid sequence intubation** at the scene of injury, with **in-line immobilisation** and cricoid pressure while lying on the ground in bright sunlight.

**A Cormack and Lehane grade 1 view of the oedematous vocal cords was readily obtained, and successful endotracheal intubation was rapidly achieved at the first attempt.** The endotracheal tube was clearly seen to pass through the vocal cords and enter the trachea.

The Airtraq required minimal manipulation to obtain a close-up, panoramic, high-grade view of the larynx.



# CR#8

## ***A managed case of difficult intubation with "Airtraq"***

Fabio Salvatore Lioni. Associazione Volontaria Interprovinciale di Soccorso

The case regards one young Austrian woman of 20 years, who remained victim of a road accident.

On delivery patient, it was reported to us that on the scene of the accident the **intubation was impossible**, for that reason it was used a laryngeal mask. Once arrived at the hospital, after some trying, the patient has been intubated with the aid of a **fibroscope**.

After a short way, arrived at the airport, during boarding procedures of the patient, the pilot balloon of the cuff was completely deflated. It was tried to inflate again the tube but without success, while the pressure obtained with the ventilations was not sufficient to maintain adequate exchanges.

**After two unsuccessful intubation attempts** – by deeper sedation-it was positioned a laryngeal mask, while we consulted our helicopter ambulance colleagues about the solutions to adopt.

**The Anesthesiologist-Resuscitator of the helicopter ambulance uses therefore the AirTraq (aircraft's equipment) for the intubation of the patient, together with an ET tube of ID 6.5. The intubation, although with some difficulties, succeeds at the first attempt.**

# CR#10

## **Experience with a patient having multiple gunshot wounds in combat**

AANA Journal – February 2008 – Vol. 76, No. 1

948th Forward Surgical Team Camp Delta, Al Kut, Iraq

A male patient revealed multiple **gunshot wounds to the chest, neck, arm and the left flank. Rapid sequence intubation** with cricoid pressure was planned. With the potential difficult intubation and airway swelling, the decision was made to use the Airtraq for its first combat trial test. The cervical spine with in-line stabilization was maintained. The ett introducer was advanced past the periglottic hematoma and atraumatically introduced. An 8.0-mm ett was placed over the introducer and advanced without difficulty.

**In this potentially difficult airway (airway hematoma and cervical spine precautions) in a combat zone from multiple gunshot wounds to the neck, the Airtraq proved to be a life-saving device.** The Airtraq allowed for full visualization of the cords without altering cervical spine traction. With this particularly difficult airway, the initial intubation attempt needed to be the optimal attempt.

**It is our belief that the Airtraq, as an independent battery-operated device, is an invaluable tool for trauma airway settings.**

## LE#5

### **The management of difficult direct laryngoscopy and intubation in a field hospital: An alternative to fiberoptic endoscopy**

JR Army Med Corps 153(3): 181-183

JL Tong, Royal Centre for Defence Medicine, Birmingham, UK.

Fiberoptic endoscopy and intubation continues to be recommended in guidelines for the management of difficult airways. **Since fibrescopes are unavailable within United Kingdom field hospitals**, an alternative is needed.

The Airtraq optical laryngoscope is a **versatile, inexpensive, single-use option, which could readily fill this void**. It is easy to use and provides a full view of the glottis when direct laryngoscopy has failed. Its introduction will reinforce existing difficult airway equipment and simplify the management of 'can ventilate - can't intubate' patients.

## LE#6

### **Video Laryngoscopy in the Prehospital Setting**

Prehospital and Disaster Medicine, May – June 2009

Lars P.Bjoernsen, University of Wisconsin hospitals and Clinics.USA

Difficult intubating conditions are encountered in approximately 7–10% of patients who require out-of-hospital, emergency, endotracheal intubation.<sup>2,3</sup>

Direct laryngoscopy always should be retained as a primary skill; however, the **video laryngoscope has the potential to be a good primary choice for the patient with potential cervical spine injury, limited jaw or spine mobility, or who is difficult to access. It also will become a rescue airway device for intubating patients with the unanticipated difficult airway.**

The role of video laryngoscopes in securing an airway for patients with head and neck trauma in the prehospital setting still is to be determined, but offers interesting possibilities.

# MS#4

## **Use of the Airtraq laryngoscope in a model of difficult intubation by prehospital providers not previously trained in laryngoscopy**

Anaesthesia, 2007, 62, pages 1061–1065

Our study results suggest that this new laryngoscope **can facilitate high rates of successful intubation in particularly challenging circumstances** represented by a combination of practitioners with only 5 min laryngoscopy training presented with a model of a Cormack and Lehane grade III/IV view.

**The Airtraq may therefore offer an effective tool to improve first-time intubation success rates and reduce the incidence of misplaced tracheal tubes** when used by trained advanced life support providers working in the testing environment of the prehospital setting.

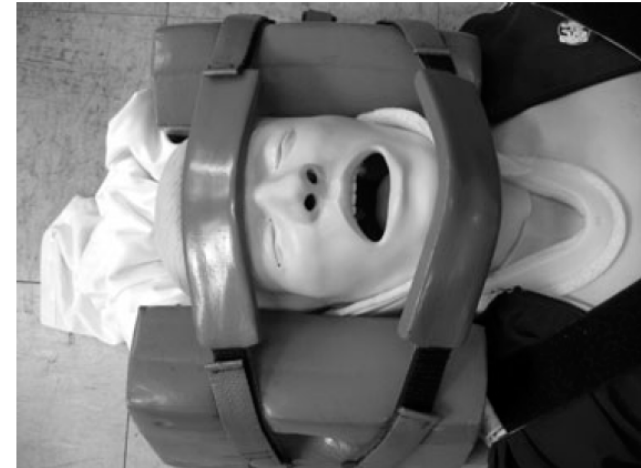

Figure 3 Manikin model of difficult intubation.

# MS#5

## *Airtraq vs standard laryngoscopy by student paramedics and experienced prehospital laryngoscopists managing a model of difficult intubation\**

Anaesthesia, 2008, 63, pages 26–31

M. Woollard. Australian College of Ambulance Professionals

The first of two studies reported in this paper aimed to determine whether use of the Airtraq by pre-employment third-year student paramedics resulted in improved intubation success rates compared with standard laryngoscopy in a manikin model of a Cormack and Lehane grade III/IV laryngoscopic view.

The second study compared the intubation success rates of experienced prehospital laryngoscopists when managing the same model of a difficult intubation using either an Airtraq or a Macintosh laryngoscope.

The studies reported in this paper have demonstrated that, **in a manikin model of difficult intubation, both student paramedics and experienced prehospital laryngoscopists rate the Airtraq as significantly easier to use than a Macintosh laryngoscope with a malleable stylet after minimal additional training.**

**Both groups achieved significantly higher first-time intubation success rates and significantly fewer failed and oesophageal intubations with the Airtraq device.**

# MS#8

## **A comparative study of Endotracheal Intubation by Airtraq, Glidescope ranger and Direct Laryngoscopy in a Closed Space Environment.**

Annals of Emergency Medicine S113, Volume 52, No 4 October 2008.

*Uniformed Services Health Education Consortium, San Antonio, TX*

A randomized crossover study was employed to assess the 3 methods of endotracheal intubation on a mannequin secured to the lowest stanchion position of a **UH-60 Blackhawk helicopter** airframe model.

Airtraq (mean = 2.885) was least difficult when compared to GSR (mean = 3.615,  $p = 0.252$ ) and DL (mean = 5.145,  $p = 0.0041$ ).

Intubation times were also improved for the ATQ compared to DL (AT = 23.810s vs. DL = 39.145s,  $P = < 0.0001$ ) and GSR (GSR = 39.295s,  $p = < 0.0001$ ).

Both ATQ and GSR provided significant improvement to CLV as rated by study subjects ( $p = 0.0006$  and  $p = 0.0047$ , respectively).

**Conclusion: The GlideScope Ranger and Airtraq devices enhanced CLV in the closed space setting, and the Airtraq reduced perceived degree of difficulty and reduced time to intubation.**

# MS#11

## **Comparison of the Airtraq® and Truview® to the Macintosh for use by Advanced Paramedics in easy and simulated difficult intubation**

BMC Emergency Medicine

Sajid Nasim\*1, Galway University Hospitals, Ireland

**Results:** The Airtraq® reduced the number of optimization manoeuvres and reduced the potential for dental trauma when compared to the Macintosh, in both the normal and simulated difficult intubation scenarios. In contrast, the Truview® increased the duration of intubation attempts, and required a greater number of optimization manoeuvres, compared to both the Macintosh and Airtraq® devices.

**Conclusion: The Airtraq® laryngoscope performed more favourably than the Macintosh and**

**Truview® devices** when used by Paramedics in this manikin study. Further studies are required to

extend these findings to the clinical setting.



# MS#12

## **Airway management at floor level: a comparison of tracheal intubation using the macintosh and Airtraq**

JR Army Med Corps 154(1): 21-25

JL Tong Department of Military Anaesthesia and Critical Care, Royal Centre for Defence Medicine, Birmingham, UK

**Sixty volunteers** attending a medical conference with **no prior Airtraq experience**, who were skilled in pre-hospital Macintosh intubation, were recruited.

Each was required to intubate an anatomically correct manikin **at floor level** using a Macintosh and Airtraq laryngoscope.

**The Airtraq was found to be superior in ease of use (VAS 30mm, P<0.001), had a shorter total intubation time (19.4seconds) and a higher intubation success rate (P=0.012) than the Macintosh laryngoscope (VAS 50mm, 20.4seconds).**

Rotating the tracheal tube 90° anticlockwise during loading into the guiding channel, made the Airtraq intubation easier (VAS 30mm, P=0.001) and faster (19.4seconds, P<0.001) than with standard orientation of the tube (VAS 40mm, 25.3seconds).

Airtraq intubation may prove to be easier than Macintosh intubation, when utilised in the clinical pre-hospital setting, though randomised controlled clinical trials are required to confirm this.

# MS#13

## **Comparison of use of the the Airtraq with direct laryngoscopy by paramedics in the simulated airway**

Thomas A. Nowicki, MD, University of Connecticut, Hartford, CT  
Prehospital Emergency Care January / March 2009 volume 13 / number 1

Thirty paramedics participated in this study. The participants then managed the following four scenarios on a Laerdal SimMan manikin placed supine on the floor..

For **Scenario 1 (Normal Airway 1)**: there were no significant differences in either the number of attempts or the time to ventilation between the devices.

For **Scenario 2 (Tongue Edema)**, the mean time to ventilation was significantly faster, and fewer intubation attempts were observed with the Airtraq when compared with DL.

For **Scenario 3 (Cervical Spine Immobilization)**, there were no significant differences in number of attempts and time to ventilation. Six participants had fewer attempts with the Airtraq.

**Scenario 4 (Normal Airway 2)** demonstrated significantly less time to ventilation and fewer intubation attempts with the Airtraq. A significant decrease in time to ventilation was observed with the Airtraq when comparing scenarios 1 and 4.

**Conclusions.** The Airtraq was shown to be equal to or faster than DL. The Airtraq has a rapid learning curve demonstrated by a significantly decreased time to ventilation between scenarios 1 and 4. We found the Airtraq Optical Laryngoscope to be equal to or faster than DL in simulated easy and difficult airway scenarios. **This device appears to have a rapid learning curve after minimal training and may be useful as a primary or backup device for out-of-hospital endotracheal intubation.** Although the Airtraq shows promise, it is not known how the device will perform in the clinical out-of-hospital environment. Our findings will need to be verified with prospective clinical trials.

## 7. Special Procedures

CLINICAL STUDIES					
Ref	Title	Published	Performed By	Hospital	Country
CS#22	Tracheal Tube Exchange: Feasibility of Continuous Glottic Viewing with Advanced Laryngoscopy Assistance	2009 International Anesthesia Research Society DOI: 10.1213/ane.0b013e3181990a82	Thomas C. Mort, MD	Hartford Hospital	USA

CASE REPORTS					
Ref	Title	Published	Performed By	Hospital	Country
CR#4	Use of the Airtraq for anticipated difficult laryngoscopy.	Anaesthesia, 2007, 62, pages 528–538	A. Norman	Worcestershire Royal Hospital	UK
CR#9	The Airtraq to facilitate endotracheal tube exchange in a critically ill, difficult-to-intubate patient.	Journal of Clinical Anesthesia (2007) 19, 485–488	A. Matic MD	William S. Middleton Memorial VA	WI, USA.
CR#13	Insertion of a transesophageal echocardiography (TEE) probe	Journal of Cardiothoracic and Vascular Anesthesia, Vol 22, No 2 (April), 2008: pp 331-339	Y. Hirabayashi, MD and N.Seo, MD	Jichi Medical University	Japan
CR#14	Use of the Airtraq with fiberoptic bronchoscope in a difficult intubation outside the operating room.	Canadian Journal of Anesthesia 55:8 August 2008.	Adrian A. Matic md,	University of Wisconsin Hospital	USA
CR#15	Airtraq® as an Intubating Conduit (Airtraq + Fibrescope).	2008 International Anesthesia Research Society. Vol. 107, No. 1, July 2008	Hiroshi Inoue, MD	Sendai Kousei Hospital	Japan
CR#19	Use of the nasotracheal Airtraq® to assist difficult nasal fiberoptic intubation	Canadian Journal of Anesthesia December 2008; 55: 12	P. Schoettker et Al.	University Hospital CHUV, Lausanne,	Switzerland

## CS#22

### **Tracheal Tube Exchange: Feasibility of Continuous Glottic Viewing with Advanced Laryngoscopy Assistance**

International Anesthesia Research Society DOI: 10.1213/ane.0b013e3181990a82

Thomas C. Mort, MD, Department of Anesthesiology, Hartford Hospital, USA

Seventy-two patients were evaluated, and 51 met the “no view” criteria. Thirty-seven patients had previous difficult intubation

Excellent visualization was possible with each of the three devices, Airtraq, Glidescope and McGrath, in the vast majority of patients.

Visualization of structures was ample for the ETT exchange and confirmation of tracheal reintubation, especially in light of the “no view” offered by conventional laryngoscopy.

Forty-seven of 49 patients (96%) were reintubated on the first attempt.

**This review supports the feasibility of using advanced laryngoscopy for ETT exchange because of its ability to offer a marked improvement in visualizing the periglottic structures in the difficult airway patient.**

# CR#4

## **Use of the Airtraq laryngoscope for anticipated difficult laryngoscopy (assistance with tracheostomy).**

Anaesthesia, 2007, 62, pages 528–538.

A. Norman. Worcestershire Royal Hospital, UK

An uneventful awake nasal fiberoptic intubation was performed, and after induction of anaesthesia the direct laryngoscopic view was noted as **Cormack and Lehane grade 4**.

**To assist the tracheostomy**, an Airtraq was used to position the cuff of the tracheal tube at the vocal cords under direct vision. An excellent view of the larynx was obtained and the tracheostomy was performed uneventfully.

Attempted examination **with a Macintosh blade was impossible**, but with an Airtraq the surgeon was able to assess the oral cavity, pharynx and laryngeal inlet adequately.

So far our experience with the Airtraq is limited to a small number of cases. Based on this experience we agree with Maharaj et al. [1, 2] that **this device is easy to use, requires minimal training and causes minimal dental trauma**. We feel that its use should be considered as part of the **management of the difficult airway including assistance with tracheostomy**.

# CR#9

## **The Airtraq to facilitate endotracheal tube exchange in a critically ill, difficult-to-intubate patient**

Journal of Clinical Anesthesia (2007) 19, 485–488

A. Matic MD. William S. Middleton Memorial VA, USA

We present the Airtraq to facilitate an ETT exchange in a difficult-to-intubate, critically ill obese patient (body mass index = 35). The intubated patient (with a **history of difficult laryngoscopy and intubation**) was transported to the operating room (OR) for an emergent abdominal surgery with a “defective” ETT pilot balloon. After rapid sequence induction, a “soft tip” Cook airway exchange catheter (Cook, Bloomington, IN) was inserted and left in situ after removal of the defective ETT.

**The Airtraq, with a number 8 ETT mounted with its bevel down (anticlockwise rotation), were railroaded over the airway exchange catheter.** The Airtraq was advanced to visualize the airway exchange catheter penetrating the glottis. Then the ETT was advanced under direct visualization over the airway exchange catheter into the trachea. The glottis was edematous, and the ETT was inserted into the trachea without trauma while cricoid pressure was maintained.

**The Airtraq ETT exchange technique may be useful in healthy and difficult-to-intubate patients as it may reduce the rate of complications and failure.**

# CR#13

## **Insertion of a transesophageal echocardiography (TEE) probe**

*Journal of Cardiothoracic and Vascular Anesthesia*, Vol 22, No 2 (April), 2008: pp 331-339

Y. Hirabayashi, N. Seo. Jichi Medical University. Japan

Similar to endotracheal intubation, the TEE probe can be inserted easily under optical control.

The Airtraq is significantly rugged compared with the TEE probe, and, hence, it is less susceptible to damage and provides easy maneuverability of the TEE probe. Even when the esophageal orifice is not identified through the viewfinder of the scope, the thick blade could provide the potential space for advancing the probe tip into the pharynx. We attempted this method in a patient with difficult blind insertion of the TEE probe and were successful in inserting the probe quickly and without any assistance.

Since that attempt, **many operators at our institution have elected to use the Airtraq to insert the TEE probe, especially in patients with difficult insertion.**

**The Airtraq-aided esophageal introduction of the TEE probe is a safe and simple method during general anesthesia.**

# CR#14

## **Use of the Airtraq® with a fiberoptic bronchoscope in a difficult intubation outside the operating room**

*CAN J ANESTH 55: www.cja-jca.org August, 2008*

Adrian A. Matic md, University of Wisconsin Hospital

A comatose 60-yr-old male, with extensive radiation therapy to the neck, required urgent tracheal intubation for respiratory failure (pneumonia). Airway examination revealed hardened neck structures, a limited mouth opening, a fixed mandible, the neck in flexion, and a reduced thyromental distance. **Two successful FOB attempts, were followed by the inability to slide either an 8.0-mm or a 7.0-mm endotracheal tube past the oropharynx.**

**Using the rotational insertion technique, a small Airtraq®, loaded with a 7.5-mm ETT, was passed through the limited mouth opening.** The glottis was fully visualized (“Cormack and Lehane grade 1 view”) in the left upper corner of the viewfinder. However, the hardened pharyngeal tissue did not allow any Airtraq® maneuvering of the glottis to the centre of the viewfinder for an optimal intubation attempt. Similarly, exterior laryngeal manipulation was ineffective.

**With the Airtraq® in situ, the pediatric FOB was advanced through the ETT.** The vocal cords were easily identified, and the ETT was advanced under direct visualization



# CR#15

## **Airtraq® as an Intubating Conduit (Airtraq + Fibrescope)**

2008 International Anesthesia Research Society

Hiroshi Inoue, MD. Sendai Kousei Hospital, Japan

After induction of anesthesia with propofol 1.5 mg/kg, fentanyl 100 g, and 0.1 mg/kg vecuronium, tracheal intubation using a Machintosh #3 laryngoscope blade could not be accomplished. The view of the vocal cord was described as Cormack-Lehane Grade 3.

Using the Airtraq, it was difficult to insert the endotracheal tube (ETT) into the trachea because the tip of the E TT was repeatedly directed posteriorly.

**Fiberoptic-guided bronchoscopy was not possible because of copious bloody secretions and a fiberoptic bronchoscope positioned inside of an ETT was inserted in the lateral channel of the Airtraq, thus using the Airtraq as an intubating conduit.**

**The vocal cords were seen in upper margin of the Airtraq viewfinder and the fiberoptic bronchoscopy passed into her trachea and the ETT was inserted.**

## CR#19

### **Use of the nasotracheal Airtraq® to assist difficult nasal fiberoptic intubation**

Canadian Journal of Anesthesia December 2008; 55: 12

P. Schoettker et Al. University Hospital CHUV, Lausanne, Switzerland

A 40-yr-old 85-kg man, was wearing a custom-made moulded **thoracocervical rigid collar due to an unstable C2 fracture**, and a Mallampati grade IV with a mouth opening of 15 mm.

Nasotracheal fiberoptic intubation with a 6.5-mm nasotracheal tube was attempted and unsuccessful due to copious bloody secretions and a collapsed orotracheal pathway.

Airtraq® was introduced through the patient's mouth while fibrescopy was still in progress. At this point, the epiglottis and vocal cords were easily visualized. The nasotracheal Airtraq® operator gave verbal directions (up, down, left, right, forward, and back) for the fibrescopy, and tracheal intubation was achieved.

**The successful completion of this case, in the face of bleeding from nasal mucosa and a limited mouth opening due to the presence of a cervical collar, illustrates a potential role for the nasotracheal Airtraq® device in a difficult nasotracheal intubation under general anesthesia.**

## 8. Pediatrics

CASE REPORTS					
Ref	Title	Published	Performed By	Hospital	Country
CR#24	Airtraq in a 5-month-old infant with a difficult airway because of Robin Sequence	Paediatric Anaesthesia 19,695-715	A. Vlatten	Pediatric Anesthesia, IWK Health Centre, Halifax	Canada
CR#25	Pediatric Airtraq® in a patient with Treacher Collins syndrome	Paediatric Anaesthesia 19,908-928	Y. Hirabayashi, MD	Jichi Medical University	Japan
CR#26	Airtraq for intubation in Treacher Collins syndrome	Paediatric Anaesthesia 19,695-715	Didier Pean	Hôtel Dieu, Nantes	France
CR#28	The Pediatric Airtraq A Possible Solution for the Treacher Collins' Airway		Tracey Straker MD MPH	Montefiore Medical Center	USA
CR#29	Intubation with an Airtraq™ of a 7-year-old child with severe cervical burned sequels	Annales Françaises d'Anesthésie et Réanimation 28 (2009) 392-400	CHU de Nantes,	C.Lejus,	France
CR#30	Successful intubation of a child with Goldenhar syndrome, who previously failed intubation, using an Airtraq	Paediatric Anaesthesia doi:10.1111/j.1460-9592.2009.03223.x	Samia Khalil	The University of Texas Medical School at Houston	USA
CR#31	Airtraq optical laryngoscope: initial clinical experience in 20 children	Japanese Society of Anesthesiologists 2009 DOI 10.1007/s00540-009-0828-2	Y. Hirabayashi, MD	Jichi Medical University	Japan
CR#32	Two consecutive uses of Infant Airtraq in antici	Service d'anesthésie pédiatrique	Lafrikh, France	Service d'anesthésie pédiatrique	France

## CR#24

### **Airtraq in a 5-month-old infant with a difficult airway because of Robin Sequence**

Paediatric Anaesthesia 19,695-715

Vlatten , Pediatric Anesthesia, IWK Health Centre, Halifax, Canada

A 5-month-old, 4.8-kg infant, born at 33-week gestation (**corrected age 3 months**) was presented for management of severe gastroesophageal reflux. The infant was born with facial dysmorphism including severe micrognathia, retrognathia, and cleft palate (**Robin Sequence**).

**Previously, at 4 months age**, the child had undergone a magnetic resonance image (MRI) scan under general anesthesia. Laryngoscopy at that time revealed a difficult airway with a **Cormack–Lehane grade 3b view of the larynx. Intubation attempts were discontinued**, and the MRI was performed under spontaneously breathing inhalational anesthesia using a laryngeal mask.

Direct laryngoscopy using a Miller 1 blade, augmented by external laryngeal manipulation resulted in a **Cormack–Lehane grade 3b view (tip of retroverted epiglottis only) and percent of glottic opening (POGO) score seen was 0%**. An Airtraq size 0 (infant) preloaded with a 3.0-mm ID microcuff endotracheal tube was inserted into the oropharynx. **The Airtraq provided a full view of the entire glottic opening (Cormack–Lehane grade 1, POGO score 100%)**. The ett was advanced along the Airtraq guide channel through the vocal cords on first attempt.

## CR#25

### **Pediatric Airtraq® in a patient with Treacher Collins syndrome**

Paediatric Anaesthesia 19,908-928

Y. Hirabayashi, N. Seo. Jichi Medical University. Japan

A 9-year-old girl with mental retardation, weighing 23 kg, was scheduled for surgical repair of atresia auris congenita

Direct laryngoscopy using the **Macintosh laryngoscope** revealed the **tip of the epiglottis but not glottic opening** (Figure 1a). An anesthesia resident inserted the pediatric AOL into the mouth and very easily captured the **full view of the vocal cords** (Figure 1b). **An endotracheal tube with cuff (internal diameter of 5.0 mm) was intubated within 40 s,**

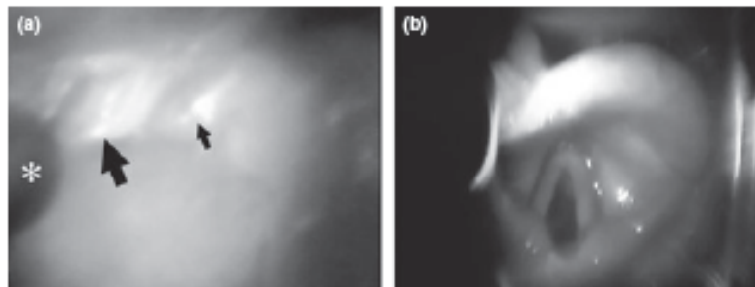


Figure 1 (a) Image taken during Macintosh laryngoscopy. Macintosh blade; thick arrow, epiglottis; thin arrow, arytenoids. Note: This image was captured by a CCD camera positioned at the right side space in the oral cavity, and thereby the image was different from the actual direct view of the laryngoscopist who could find the tip of the epiglottis only. (b) Glottic exposure using the pediatric Airtraq® optical laryngoscope handled by an anesthesia resident, who performed successful tracheal intubation within 40 s.

## CR#26

### **Airtraq® in a patient with Treacher Collins syndrome**

Paediatric Anaesthesia 19,695,715

Didier Pean, Department of Anesthesiology and Critical Care, Hôtel Dieu, Nantes, France

Preoperative evaluation revealed a 10-year-old female (28 kg and 137 cm) with no other medical history. All characteristics of Treacher Collins syndrome were noticed including a previously repaired cleft palate. Difficult intubation was related for a previous tympanoplasty, but intubation procedure was unknown.

Direct laryngoscopy with a no. 3 Macintosh metal blade permit only visualization of Cormack 3 class. The gum elastic bougie was not used because the oro pharyngeal angulations' seems too small and the epiglottis was completely stucked on the posterior pharyngeal wall.

After face mask ventilation, the Airtraq device (size 2; Small Adult) was easily introduced and the glottis was immediately visualized. Two intubation attempts failed because tracheal tube takes always a posterior way under the glottis despite adjustments of the Airtraq distal position. Finally, a gum elastic bougie was advanced through the Airtraq lateral channel and easily introduced through the glottis. Intubation was realized with a 5.5-ID-armored tracheal tube.

Difficulties was encountered because we use a size 2 device, recommended for 6–7.5 ID tracheal tubes (a size 1 device was not available in France at this time), **but intubation was easily performed with the help of a gum elastic bougie. Airtraq is a good alternative to fiberoptic intubation for difficult intubation in a Treacher Collins syndrome child, an appropriate size is recommended.**

## CR#28

### **The Pediatric Airtraq A Possible Solution for the Treacher Collins' Airway**

Tracey Straker MD. MPH, Montefiore Medical Center

A 9 year old boy, 20.7kg, with a history of Treachery Collins Syndrome was scheduled for craniofacial reconstruction. He had multiple surgeries for cleft palate and microtia, in which his airway had been secured by spontaneously breathing fiberoptic intubation.

The previous fiberoptic intubations were with considerable difficulty. A CA 1 resident prepared for the Treacher Collins' case with the pediatric Airtraq the day before by intubating a pediatric mannequin once. The CA 1 resident **was able to successfully** intubate the child without any difficulty or aid from an attending.

**Conclusion:** It can be concluded that the **pediatric Airtraq can be a valuable device in the securing of a known difficult airway**, and may be of value in an unanticipated difficult airway.

**Instruction with the pediatric Airtraq is minimal** and successful intubation afterwards can be achieved.

## CR#29

### **Intubation with an Airtraq™ of a 7-year-old child with severe cervical burned sequels**

Annales Françaises d'Anesthésie et Réanimation 28 (2009) 392-400

C.Lejus, CHU de Nantes, France

Ventilation through face mask was difficult and required using two hands without pressing the maxilar bone.

Previous intubation of the patient took 5 minutes and a Frova stylet was needed. The patient was a **Cormack 3**.

Preoperative examination determined an important **limitation of the cervical extension** and the **intubation was predicted as difficult**.

The pediatric Airtraq is used as a first intubation option without any direct laryngoscopy attempt.

**Glottis visualization is perfect** and a 5.5 cuffed ETT is performed in less than 30 seconds at the first attempt.

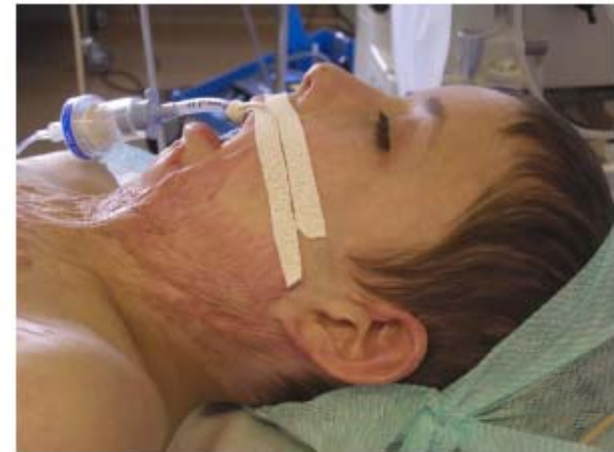

Fig. 1.



## CR#30

### **Successful intubation , using an Airtraq, of a child with Goldenhar syndrome, who previously failed intubation**

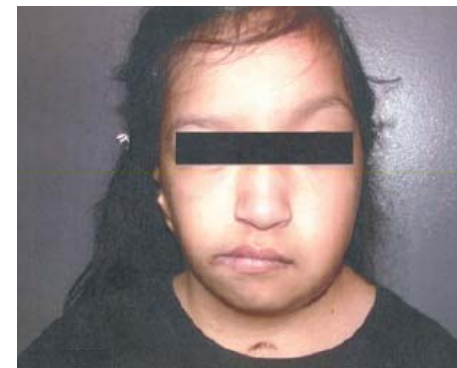Pediatric Anesthesia, Medical doi:10.1111/j.1460-9592.2009.03223.x

S. KHALIL\* , The University of Texas Medical School at Houston, TX, USA

She had previous surgery to enlarge the right side of her mandible using a bone graft. At that time, an elective **preoperative tracheostomy was performed** for perioperative airway management. The child was scheduled for the microtia repair **1 week earlier at our institution and had failed intubation.**

Using a child's Airtraq, size 2, we were **able to clearly see** the glottis, the vocal cords and the passage of the cuff of the endotracheal tube beyond the vocal cords.

We were able to place the cuffed orotracheal tube, size 5.5, on **the first attempt, without difficulty and in a very short time**



# CR#31

## **Airtraq optical laryngoscope: initial clinical experience in 20 children**

Japanese Society of Anesthesiologists 2009, DOI 10.1007/s00540-009-0828-2

Yoshihiro Hirabayashi, Jichi medical University, Japan

Endotracheal intubation using the Airtraq was always successful.

**Case 5** was a patient with Treacher Collins syndrome. A malleable stylet facilitated introduction of the tube tip into the tracheal inlet on the second attempt, resulting in successful intubation.

**Case 12** required two maneuvers to align the tube tip with glottic opening.

**Case 19** had a large cleft lip and palate and the Macintosh laryngoscope failed to expose the glottis.

Intubation was performed by the infant Airtraq after two failed attempts. **The Airtraq is likely to provide advantages in glottic exposure, even in children with high and anterior-positioned glottis.**

The Airtraq seems a **safe** and **beneficial** device for tracheal intubation in young children.

**Table 1** Experience with the Airtraq optical laryngoscope (AOL) for tracheal intubation in infants and young children

Case	Age	Weight (kg)	AOL <sup>a</sup>	Tube ID (mm)	Attempts <sup>b</sup>	Time <sup>c</sup> (s)
1	18 months	11.6	P	4	1	30
2	14 months	11.0	P	4.5	1	45
3	7 months	7.4	P	4	1	76
4	2 months	3.1	I	3	1	44
5	9 years <sup>d</sup>	22.6	P	5 <sup>e</sup>	1	40
6	20 months	11.0	P	4	1	50
7	2 years	12.5	P	4.5	1	53
8	18 months	8.6	P	5 <sup>f</sup>	1	50
9	10 days	3.1	I	3	2	95
10	4 years	16.3	P	5	1	46
11	15 months	10.6	P	4.5	1	47
12	16 months	9.9	P	4 <sup>f</sup>	2	122
13	14 months	8.3	P	4	1	35
14	12 months	7.9	P	4	1	55
15	3 months <sup>g</sup>	6.0	I	3.5	1	35
16	7 months	7.4	P	4	1	32
17	15 months	9.1	P	4.5	1	60
18	6 years	20.0	P	5.5 <sup>f</sup>	1	25
19	3 months	4.3	P	4 <sup>f</sup>	3	167
20	14 days	3.5	I	3.5	1	53

<sup>a</sup> Size of Airtraq optical laryngoscope: I, infant; P, pediatric

<sup>b</sup> Number of attempts to successful intubation

<sup>c</sup> Time to completion of endotracheal intubation

<sup>d</sup> Treacher Collins syndrome

<sup>e</sup> Tube with cuff

<sup>f</sup> Preformed tube (RAE oral, Mallinckrodt, Athlone, Eire)

<sup>g</sup> Pfeiffer syndrome

## CR#32

### **Two consecutive uses of Infant Airtraq in anticipated difficult intubation**

Annales Françaises d'Anesthésie et de Réanimation xxx (2010) xxx–xxx

A. Lafrikh, CHU de Bordeaux,, France

We used successfully Airtraq-combined to a gum-elastic boogie to intubate twice a dysmorphic infant with mucopolidosis, in whom direct laryngoscopy failed.

If this result is confirmed by prospective studies, Airtraq could be **a first-line device to intubate infants** with difficult intubation.

## 9. Nasotracheal

CLINICAL STUDIES					
Ref	Title	Published	Performed By	Hospital	Country
CS#16	Airtraq laryngoscope has an advantage over Macintosh laryngoscope for nasotracheal intubation by novice laryngoscopists	J Anesthesia (2009) 23:172–173	Yoshihiro Hirabayashi and Norimasa Seo	Jichi Medical University	Japan
CS#20	Cuff inflation as an aid to nasotracheal intubation using the Airtraq	Can J Anesth/J Can Anesth DOI 10.1007/s12630-010-9285-5	F. S. Xue, MD	Chinese Academy of Medical Sciences and Peking Union Medical College, Beijing	China
CS#24	Nasal Endotracheal Intubation – Airtraq Technique vs. Macintosh Blade	2010 ASA Abstracts	Harald V. Genzwuerker, M.D	Clinic of Anaesthesiology and Intensive Care medicine	Germany
CS#25	Comparison of Airtraq with Conventional Laryngoscopy in 50 ENT Patients Undergoing Microlaryngoscopy	2011 ASA Abstracts	Neal Samuels, F.R.C.A	St. Bartholomews' Hospital, West Smithfield	UK

## 9. Nasotracheal

CASE REPORTS					
Ref	Title	Published	Performed By	Hospital	Country
CR#19	Use of the nasotracheal Airtraq® to assist difficult nasal fiberoptic intubation	Canadian Journal of Anesthesia December 2008; 55: 12	P. Schoettker et Al.	University Hospital CHUV, Lausanne,	Switzerland

MANIKIN STUDIES					
Ref	Title	Published	Performed By	Hospital	Country
MS#6	Nasotraqueal Intubation Using the Airtraq versus Macintosh Laryngoscope.	Anesth Prog 55:78-81 2008	Y. Hirabayashi, MD and N.Seo, MD	Jichi Medical University	Japan

# CS#16

## *Airtraq laryngoscope has an advantage over Macintosh laryngoscope for nasotracheal intubation by novice laryngoscopists*

J Anesthesia (2009) 23:172–173

Yoshihiro Hirabayashi and Norimasa Seo , Jichi Medical University, Tochigi , Japan

We studied 20 patients who required nasotracheal intubation. Each intubation was performed by a non-anesthesia physician with 1–2 months of training in airway management.

Our study demonstrates that, in comparison with the Macintosh laryngoscope, the Airtraq laryngoscope provides superior intubation conditions for personnel who are training in airway management, resulting in **less time to secure the airway**.

No patient in the Airtraq group experienced esophageal intubation, while one resident performed an esophageal intubation in the Macintosh group.

In the present study, **Magill forceps were not needed** for any patient for nasotracheal intubation with Airtraq laryngoscopy.

# CS#20

## **Cuff inflation as an aid to nasotracheal intubation using the Airtraq®**

*Can J Anesth/J Can Anesth DOI 10.1007/s12630-010-9285-5 S.*

*Fu S.Xue,MD Chinese Academy of Medical Sciences and Peking Union Medical College, Beijing*

We recruited **72 patients** . A nasotracheal tube was inserted via the preselected nostril until the tube tip passed through the posterior larynx. Next, an orotracheal Airtraq was passed into the patient's mouth over the tongue in the midline. If the tube tip failed to be aligned with the glottis, the tube was withdrawn until the cuff was below the distal end of the Airtraq.

**At this position, an assistant slowly inflated the cuff with a 20 mL syringe until the tube tip was aligned with the visualized glottis** Then, the tube was re-advanced an additional 1.0 to 1.5 cm to pass the glottis., deflated and the tube was inserted into the trachea.

Nasotracheal intubation was successful in 49 of the 72 patients at the first attempt without cuff inflation. However, in the remaining 23 patients, the nasotracheal tube tip could not be brought into alignment with the glottis during the initial intubation attempt. Sixteen of the 23 incorrect tube tip locations were posterior tip positions and seven were lateral tip positions.

**By inflating the cuff in these cases, the nasotracheal tube tip was directed satisfactorily toward the glottis and NTI was successfully completed.** The air volume required for cuff inflation was  $12.5 \pm 3.2$  mL with a range from 8-18 mL. We observed through the viewfinder that cuff inflation could produce upward and central movements of the nasotracheal tube tip to align with the glottis located in midline

# CS#24

## Nasal Endotracheal Intubation – Airtraq Technique vs. Macintosh Blade

Harald Groeben, MD, Clinics Essen-Mitte, Germany

ASA 2009 Abstract

**One hundred patients**, scheduled for general anesthesia with nasal endotracheal intubation for maxillo-facial surgery, were randomized to be intubated via direct laryngoscopy (n=50) or Airtraq laryngoscopy (n=50) by two experienced anesthesiologists. **The visualization of the glottis according to Cormack & Lehane was significantly improved with the Airtraq technique.**

**Conclusion:** Nasal endotracheal intubation in patients with normal airways can be performed with the nasal Airtraq as efficient as with the Macintosh blade with a significantly better view of the laryngeal entrance. **In 96% of the patients intubation was managed without a Magill forceps.**

Figure 1

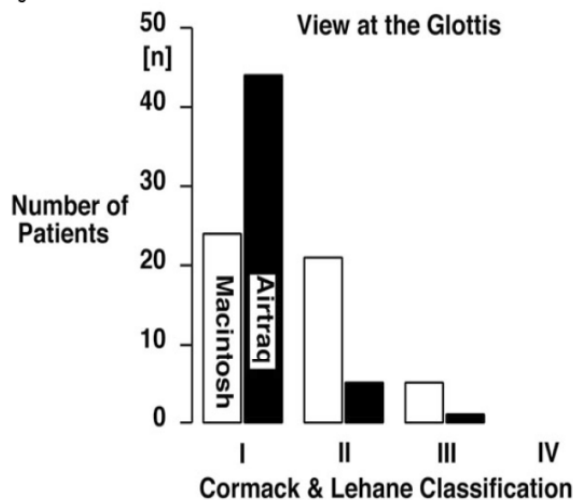
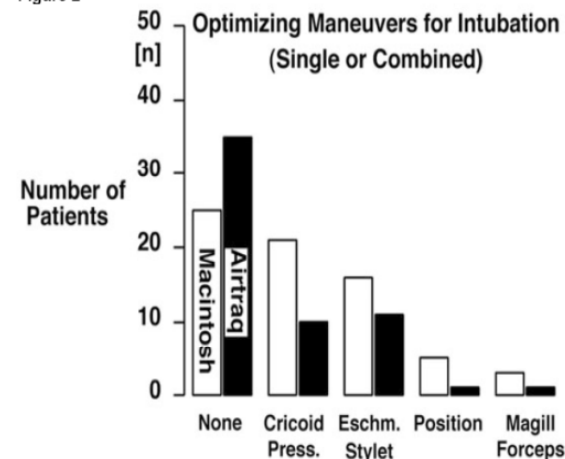


Figure 2





# CS#25

## Comparison of Airtraq with Conventional Laryngoscopy in 50 ENT Patients Undergoing Microlaryngoscopy

ASA 2009 Abstract

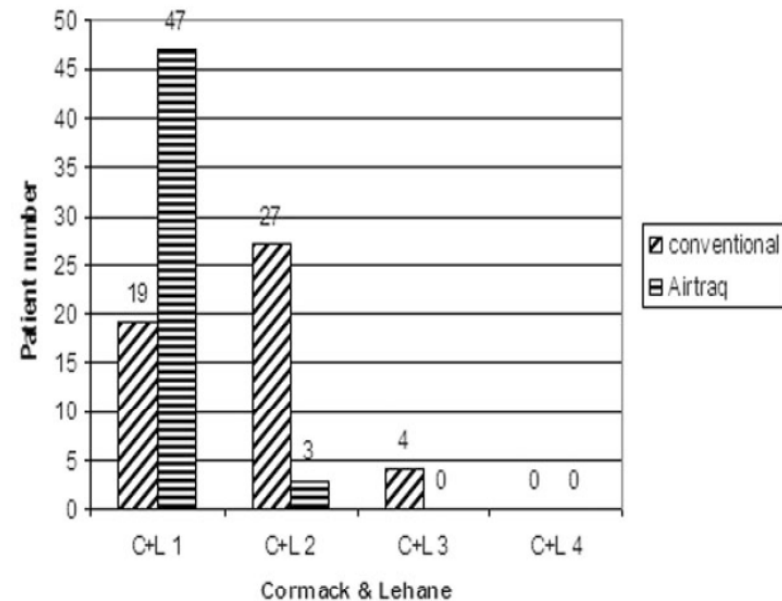
Harald V. Genzwuerker, M.D, Neckar-Odenwald-Kliniken , Buchen and Mosbach, Germany

Laryngoscopic view was obtained with a Macintosh blade by an anesthesia resident with 2 years of training in **50 adult** patients before intubation was attempted with the Airtraq by the same operator. Cormack and Lehane score was used to compare glottic view.

**Conclusion:** In ENT patients presenting for microlaryngoscopical surgery, **laryngoscopic view is improved with the Airtraq®** when compared to conventional laryngoscopy with a Macintosh blade.

**Better view may lead to less trauma and swelling at the glottic inlet caused by intubation, facilitating planned procedures.**

Laryngoscopic views conventional technique vs .Airtraq



## CR#19

### **Use of the nasotracheal Airtraq® to assist difficult nasal fiberoptic intubation**

Canadian Journal of Anesthesia December 2008; 55: 12

P. Schoettker et Al. University Hospital CHUV, Lausanne, Switzerland

A 40-yr-old 85-kg man, was wearing a custom-made moulded **thoracocervical rigid collar due to an unstable C2 fracture**, and a Mallampati grade IV with a mouth opening of 15 mm.

Nasotracheal fiberoptic intubation with a 6.5-mm nasotracheal tube was attempted and unsuccessful due to copious bloody secretions and a collapsed orotracheal pathway.

Airtraq® was introduced through the patient's mouth while fibrescopy was still in progress. At this point, the epiglottis and vocal cords were easily visualized. The nasotracheal Airtraq® operator gave verbal directions (up, down, left, right, forward, and back) for the fibrescopy, and tracheal intubation was achieved.

**The successful completion of this case, in the face of bleeding from nasal mucosa and a limited mouth opening due to the presence of a cervical collar, illustrates a potential role for the nasotracheal Airtraq® device in a difficult nasotracheal intubation under general anesthesia.**

# MS#6

## **Nasotraqueal Intubation Using the Airtraq versus Macintosh Laryngoscope.**

Anesth Prog 55:78-81 2008,

Y. Hirabayashi, N. Seo. Jichi Medical University. Japan

**Nasotracheal intubation on a manikin** was performed by 20 anesthesiologists and 20 residents with the Airtraq or Macintosh laryngoscope.

The mean (6 SD) time required for nasotracheal intubation by the residents was significantly shorter with the Airtraq laryngoscope than with the Macintosh laryngoscope (16 67 sec vs 2 26 10 sec;  $P < .001$ ), but no difference in intubation time was observed between Airtraq (15 6 11 sec) and Macintosh (13 6 6 sec) laryngoscopy by the anesthesiologists.

**The Magill forceps was used more frequently to facilitate intubation with the Macintosh laryngoscope than with the Airtraq laryngoscope in both groups of operators 7( $P < .001$ ).**

**The Airtraq laryngoscope scored better on the visual analog scale than did the Macintosh laryngoscope in both groups of operators ( $P < .05$ ).**

**The Airtraq laryngoscope offers potential advantages over standard direct laryngoscopy for nasotracheal intubation**

## 10. Double Lumen / B. Blocker

CLINICAL STUDIES					
Ref	Title	Published	Performed By	Hospital	Country
CS#6	The Airtraq® laryngoscope for placement of double-lumen endobronchial tube.	Canadian Journal of Anesthesia 54:955-957	Y. Hirabayashi, MD and N.Seo, MD	Jichi Medical University	Japan

CASE REPORTS					
Ref	Title	Published	Performed By	Hospital	Country
CR#20	Airtraq laryngoscope for bronchial blocker placement in a difficult airway	Anaesthesia, 2009, 64, pages 687–697	G. DeGregoris; S. S. Hill; R. L. Slepian	NewYork- Presbyterian Hospital	USA

## CS#6

### **The Airtraq® laryngoscope for placement of double-lumen endobronchial tube**

Canadian Journal of Anesthesia 54:955-957 (2007)

Y. Hirabayashi, MD and N.Seo, MD. Jichi Medical University, Japan

The Airtraq® laryngoscope allowed placement of 35- and 37-French DLTs in **ten patients** without complications. Based on our experience, the Airtraq® laryngoscope accepts 35- and 37-French DLTs, although the latter was somewhat thick against the channel of the scope. It is probably impossible to insert a 39-French DLT (outer diameter = 13 mm).

Despite this limitation, the Airtraq® laryngoscope appears to be an alternative approach for DLT placement when the physician encounters cases in which the conventional Macintosh laryngoscopy results in unsuccessful DLT placement.

**Note: The cases were performed using a Regular size Airtraq. A new Airtraq model specifically designed to accommodate DLT tubes up to 41-French will soon be available.**

## CR#20

### **Airtraq for bronchial blocker placement in a difficult airway**

Anaesthesia, 2009, 64, pages 687–697

G. DeGregoris; S. S. Hill; R. L. Slepian

A middle-aged male presented for left thoracotomy his body mass index was 37.0 kg.m<sup>2</sup> and he had a Mallampati score of 3, with a thyromental distance of three finger breadths.

After monitoring and a pre-induction arterial line, **the patient's airway was treated with 4% lignocaine topically. A large size Airtraq laryngoscope was then easily placed into the pharynx with minimal response from the patient. A Cormack–Lehane grade I view was obtained quickly and it was consequently decided to induce general anaesthesia.**

After induction, the Airtraq laryngoscope was re-introduced, and a size 8 / 14 French Syntel **bronchial blocker was placed in the airway channel. The blocker was advanced via the Airtraq through the vocal cords.** It was then disengaged from the channel, **while the Airtraq remained in place. An 8.0 mm tracheal tube was then placed into the now vacant channel and advanced through the vocal cords.**

The Airtraq provided final visual confirmation that both the tracheal tube and bronchial blocker were placed through the vocal cords and the device was withdrawn.

Our experience adds addition evidence for the usefulness of the Airtraq laryngoscope in placement of airway devices.

## 11. Techniques & Learning Curve

CLINICAL STUDIES					
Ref	Title	Published	Performed By	Hospital	Country
CS#5	A comparison of two techniques for inserting the Airtraq™ laryngoscope in morbidly obese patients.	Anaesthesia, 2007, 62, pages 774–777.	G. Dhonneur	Jean Verdier Public University Hospital of Paris	France
CS#14	Airtraq tracheal intubation by novice laryngoscopists	Emergency Medicine Journal 2009; 26; 112-113	Y. Hirabayashi, MD and N.Seo, MD	Jichi Medical University	Japan
CS#15	Optimising tracheal intubation success rate using the Airtraq laryngoscope	Anaesthesia, 2009, 64, pages 315–319	G. Dhonneur	Jean Verdier University Hospital of Paris	France
CS#19	Effect of cricoid pressure on the laryngoscopic view by Airtraq in elective caesarean section: a pilot study	European Journal of Anaesthesiology 2009, 26:000–000	Waleed Riada and Tarek Ansarib	King Khaled Hospital Riyadh & bAl Corniche Hospital , Abu Dhabi	Saudi &UAE
CS#21	Teaching and Training of Non Anaesthesia Residents in Orotracheal Intubation with the Airtraq Wireless Monitor	Internet Journal of Airway Management Volume 5 (January 2008 to December 2009)	Schirin M. Missaghi, MD	Empress Elisabeth Hospital Vienna	Austria

## 11. Techniques & Learning Curve

LETTERS TO THE EDITOR					
Ref	Title	Published	Performed By	Hospital	Country
LE#6	Video Laryngoscopy in the Prehospital Setting	Prehospital and Disaster Medicine, May – June 2009, <a href="http://pdm.medicine.wisc.edu">http://pdm.medicine.wisc.edu</a>	Lars P. Bjoernsen, MD	University of Wisconsin Hospitals and Clinics	USA
LE#7	Airway topical anaesthesia and awake tracheal intubation using the Airtraq® laryngoscope alone	ACTA Anaesthesiol Scand 2009; 53: 964–967	FU S. Xue, MD	Chinese Academy of Medical Sciences, Beijing	China
LE#8	A simple maneuver to facilitate tracheal intubation using the Airtraq® laryngoscope with a reinforced endotracheal tube	DOI 10.107/s12630-003-9257-9	FU S. Xue, MD	Chinese Academy of Medical Sciences, Beijing	China

MANIKIN STUDIES					
Ref	Title	Published	Performed By	Hospital	Country
MS#2	Learning and performance of tracheal intubation by novice personnel: a comparison of the Airtraq and Macintosh laryngoscope.	Anaesthesia. 2006 Jul;61(7):671-7.	Maharaj CH et Al.	Univ. Of Ireland, Galway	Ireland
MS#3	Tracheal intubation by inexperienced medical residents using the Airtraq and Macintosh laryngoscopes - a manikin study.	The American J. of Emergency Med., Vol. 24, Issue 7, Nov.2006, P.769-774	Maharaj CH et Al.	Univ. Of Ireland, Galway	Ireland
MS#9	In-line head and neck position is preferable for tracheal intubation with Airtraq laryngoscope compared to the sniffing position.	Journal of Anesthesia 2008, 22:189-190.	Y. Hirabayashi, MD and N.Seo, MD	Jichi Medical University	Japan
MS#10	Comparison of the Glidescope , the McGrath , the Airtraq and the Macintosh laryngoscopes in simulated difficult airways* G. L.	Anaesthesia, 2008, 63, pages 1358–1364	Savoldelli et Al.	University of Geneva	Switzerland



# CS#5

## **A comparison of two techniques for inserting the Airtraq laryngoscope in morbidly obese patients**

Anaesthesia, 2007, 62, pages 774–777.

G. Dhonneur. Jean Verdier Public University Hospital of Paris

For the reverse manoeuvre the laryngoscope is inserted 180° opposite to that recommended, and once in place rotated into the conventional pharyngeal position.

The reverse manoeuvre did not influence tracheal intubation characteristics in the group of lean patients. In the group of morbidly obese patients, the standard technique of insertion was not satisfactory in 20% of cases and the reverse manoeuvre facilitated, speeded and secured tracheal intubation.

**In conclusion, we have demonstrated that the reverse manoeuvre of inserting the Airtraq laryngoscope was effective in facilitating tracheal intubation, shortening the duration of the procedure and reducing the risk of upper airway trauma in morbidly obese patients.**

# CS#14

## **Airtraq tracheal intubation by novice laryngoscopists**

*Emerg. Med. J.* 2009;26;112-113113doi:10.1136/emj.2008.059659

Yoshihiro Hirabayashi, Norimasa Seo, Jichi Medical University, Japan

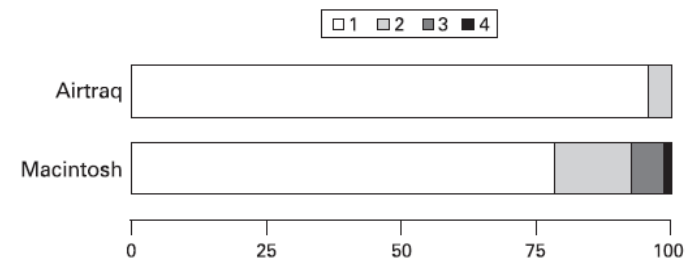
Under supervision by staff anaesthetists, **nonanaesthesia physicians** performed tracheal intubation using either the **Airtraq (n = 100)** or the Macintosh laryngoscope (n = 100).

The **time to secure the airway was shorter with the Airtraq** than with the Macintosh laryngoscope (p,0.001).

The **number of attempts until successful intubation was smaller with the Airtraq** than with the Macintosh laryngoscope (p,0.001).

**Erroneous oesophageal intubation was less with the Airtraq optical laryngoscope** than with the Macintosh laryngoscope (p,0.01).

Differences in tracheal intubation procedure using the Airtraq and Macintosh laryngoscopes by non-anaesthesia novice physicians			
	<b>Airtraq</b>	<b>Macintosh</b>	<b>p Value</b>
Time to intubation, in seconds (SD)*	51 (17)	67 (43)	0,001
Erroneous intubation of the oesophagus	0	10	0,01



**Figure 2** The number of attempts until successful intubation using the Airtraq and Macintosh laryngoscope by non-anaesthesia novice physicians. Mann-Whitney U test showed the significant difference between the two groups (p<0.001).


# CS#15

## Optimising tracheal intubation success rate using the Airtraq laryngoscope

Anaesthesia, 2009, 64, pages 315–319

G. Dhonneur, Jean Verdier University Hospital of Paris, France

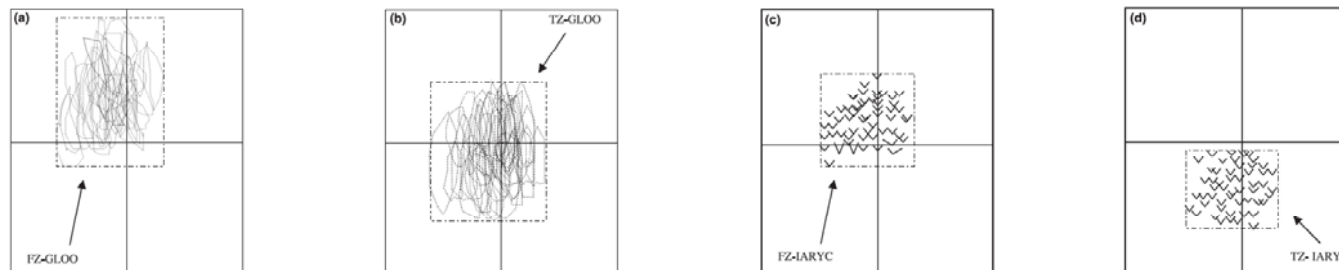
We have used a video-recording, retrospective analysis technique to demonstrate that successful tracheal intubation using the Airtraq laryngoscope require the glottic opening to be centred in the view, and positioning the inter-arytenoid cleft medially below the horizontal line in the centre of the view.



On each image (a) immediately prior to a tracheal intubation attempt, the outlines of the glottic opening and the position of the inter-arytenoids cleft immediately adjacent to posterior glottis were marked (b).

Represent schematic illustrations of the marks superimposed for glottic opening (a, b) and for the inter-aritenoid cleft (c, d) positions, just prior to failed (a, c: n = 59) and successful (b, d: n = 50) tracheal intubation attempts.

The downback-up manoeuvre and the reduction of cervical spine extension invariably moved the glottic opening and lowered its position in the laryngoscopic view. By using the down-back-up manoeuvre and the alignment of the head and neck, the glottic opening and the inter-arytenoid cleft position changed from the FZ to the TZ.



FZ and the TZ of the inter-arytenoid cleft position associated with failure and success of tracheal intubation attempts did not overlap indicating that **the inter-arytenoid cleft position is a predictor of tracheal intubation success** 115  
**using the Airtraq laryngoscope.**

# CS#19

## **Effect of cricoid pressure on the laryngoscopic view by Airtraq in elective caesarean section: a pilot study**

European Journal of Anaesthesiology 2009, 26:000–000

King Khaled Eye Specialist Hospital, Riyadh, Saudi Arabia and bAl Corniche Hospital , Abu Dhabi, United Arab Emirates

The purpose of this observational study was to assess the effect of cricoid pressure on the ease and time for successful intubation using the Airtraq optical laryngoscope to **10 consecutive pregnant patients.**

Once consciousness was lost, double-handed cricoid pressure was applied by another anaesthesiologist with the head and neck in the optimal intubating position and maintained until the airway was secured using a tracheal tube.

The trachea for all parturients was successfully intubated at the first attempt without the need for any external manipulation. **In the presence of cricoid pressure using the Airtraq, the mean duration of intubation was 25.8 s, which is markedly shorter than using Macintosh laryngoscopy in our previous report [6].**

# CS#21

## **Teaching and Training of Non Anaesthesia Residents with the Airtraq using the Airtraq Wireless Monitor for Instruction**

Internet Journal of Airway Management Volume 5 (January 2008 to December 2009)

Missaghi SM, , Austria

**Sixty four adult patients undergoing elective thyroid surgical procedures** were investigated. Patients with a previously experienced difficult conventional tracheal intubation, anatomic features predictive for difficult CL and tracheal intubation, and/or obesity were given referential enrollment into the study. The operators (3 emergency medicine residents and one surgical resident) had less experiences with AM techniques on patients and were novice users of the Airtraq.

Grades 1 to 4 at CL were obtained in 25, 16, 13, and 10 patients, respectively. **The success rate of Airtraq assisted tracheal intubation at the first attempt was 100 percent (64/64 patients).** Provided formal instruction (supported by the AWM) and supervision, the success of Airtraq assisted orotracheal intubation performed by nonanesthesia residents was not affected by CLV. **For operators responsible for emergency AM with less experiences and opportunities in these techniques, the Airtraq may be uniquely useful for routine and difficult laryngoscopy and tracheal intubation.**

## LE#6

### **Video Laryngoscopy in the Prehospital Setting**

Prehospital and Disaster Medicine, May – June 2009

Lars P.Bjoernsen, University of Wisconsin hospitals and Clinics.USA

Difficult intubating conditions are encountered in approximately 7–10% of patients who require out-of-hospital, emergency, endotracheal intubation.<sup>2,3</sup>

Direct laryngoscopy always should be retained as a primary skill; however, the **video laryngoscope has the potential to be a good primary choice for the patient with potential cervical spine injury, limited jaw or spine mobility, or who is difficult to access. It also will become a rescue airway device for intubating patients with the unanticipated difficult airway.**

The role of video laryngoscopes in securing an airway for patients with head and neck trauma in the prehospital setting still is to be determined, but offers interesting possibilities.

## LE#7

### **Airway topical anaesthesia and awake tracheal intubation using the Airtraq® Laryngoscope alone**

Acta Anaesthesiol Scand 2009; 53: 964–7.

Chinese academy of Medical sciences and Peking union medical College. Fu Shan Xue

We find that after topical anaesthesia of the mouth and pharynx with the atomized lidocaine, and sedation management with intravenous fentanyl and midazolam, the patient may well tolerate the insertion of the Airtraq and the superior laryngeal vision can be obtained by the Airtraq. We prefer to use aMADgic® laryngotracheal atomizer (MAD-LTA) to provide topical anaesthesia of the larynx, the infraglottic area and the trachea under direct vision on the viewfinder of the Airtraq.

When the glottis is in the centre of the viewfinder, the curved applicator portion of a MAD-LTA is advanced through the lateral channel of the AL and its tip is in order positioned immediately superior to the glottis and the bilateral pyriform recess under direct vision on the viewfinder.

Our experience suggests that this technique is non-invasive and does not carry the potential risk of airway damage. Also, it is easy to perform and can provide excellent topical anesthesia of the airway.

## LE#8

### **A simple maneuver to facilitate tracheal intubation using the Airtraq® laryngoscope with a reinforced endotracheal tube**

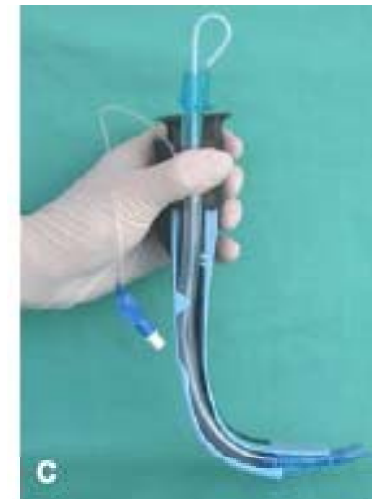Can J Anesth DOI 10.107/s12630-003-9257-9

Chinese Academy of Medical Sciences, Fu S. Xue, MD Beijing

Our own clinical experience suggests that a posterior ETT tip location is a common problem during tracheal intubation with the Airtraq® laryngoscope, the ETT and the tip of the Airtraq® laryngoscope is a contributing factor to the problem. This problem may be exacerbated whenever a thin reinforced ETT is used.

We then insert a flexible intubating stylet into the reinforced ETT. The distal end of the reinforced ETT with an intubating stylet is angled upwards very slightly and then placed at a position close to the tip of the Airtraq® laryngoscope. When it is confirmed that the reinforced ETT tip has passed the glottis, the intubating stylet is withdrawn and the reinforced ETT is then advanced downward into the trachea.

**To facilitate smooth advancement of the reinforced ETT, a flexible stylet and an adequately lubricated tube conduit of the Airtraq® laryngoscope are essential.**





# MS#2

## **Learning and performance of Tracheal intubation by novice personnel: A comparison of the Airtraq® and Macintosh laryngoscope.**

Anaesthesia, 2006;61:671-7.

Maharaj CH et Al. Univ. Of Ireland, Galway

The AIRTRAQ provided superior intubating conditions, resulting in greater success of intubation, particularly in the difficult laryngoscopy scenarios.

In both easy and simulated difficult laryngoscopy scenarios, the AIRTRAQ **decreased the duration of intubation attempts, reduced the number of optimisation manoeuvres required, and reduced the potential for dental trauma.**

The AIRTRAQ device showed **a rapid learning** curve and the students found it significantly **easier to use.**

The AIRTRAQ appears to be **a superior device for novice personnel** to acquire the skills of tracheal intubation.“

# MS#3

## **Tracheal intubation by inexperienced medical residents using the Airtraq® and Macintosh laryngoscope - A manikin study.**

The American Journal of Emergency Medicine. Vol.24, Issue 7, Pag 769-774  
Maharaj CH et Al. Univ. Of Ireland, Galway

In all scenarios tested, the Airtraq® **decreased the duration** of intubation attempts, **reduced the number of optimization maneuvers** required, and **reduced the potential for dental trauma.**

The residents found the Airtraq® **easier to use** in all scenarios compared to the Macintosh laryngoscope.

**The Airtraq® may constitute a superior device for use by personnel infrequently required to perform tracheal intubation.**

## MS#9

### **In-line head and neck position is preferable for tracheal intubation with the Airtraq laryngoscope compared to the sniffing position**

Journal of Anesthesia (2008) 22:189–190

Yoshihiro Hirabayashi, Norimasa Seo, Jichi Medical University, Japan

20 anesthetists performed tracheal intubations on a manikin with either an **in-line head and neck position** or the **sniffing position**.

There were no differences in the success rate and the time to intubation between the two positions. The overall number of teeth clicks was lower in the in-line head and neck position than in the sniffing position ( $P < 0.05$ ). The score for preference of position, on a visual analogue scale, was better for the in-line head and neck position than for the sniffing position ( $P < 0.01$ ).

**We concluded that the in-line head and neck position was preferable for tracheal intubation with the Airtraq laryngoscope compared to the sniffing position.**

# MS#10

## **Comparison of the Glidescope, the McGrath, the Airtraq and the Macintosh laryngoscopes in simulated difficult airways**

Anaesthesia, 2008, 63, pages 1358–1364

Savoldelli et Al. University of Geneva

Sixty anaesthesia providers (20 staff, 20 residents, and 20 nurses) were enrolled into this study. The volunteers intubated the trachea of a **Laerdal SimMan manikin in three simulated difficult airway scenarios.**

In all scenarios, indirect laryngoscopes provided better laryngeal exposure than the Macintosh blade and appeared to produce less dental trauma.

In the most difficult scenario (tongue oedema), the Macintosh blade was associated with a high rate of failure and prolonged intubation times whereas indirect laryngoscopes improved intubation time and rarely failed. Indirect laryngoscopes were judged easier to use than the Macintosh.

**The Airtraq consistently provided the most rapid intubation. Laryngeal grade views were superior with the Airtraq and McGrath than with the Glidescope.**

## 12. Airtraq vs. Other Video L.

CLINICAL STUDIES					
Ref	Title	Published	Performed By	Hospital	Country
CS#22	Tracheal Tube Exchange: Feasibility of Continuous Glottic Viewing with Advanced Laryngoscopy Assistance	2009 International Anesthesia Research Society DOI: 10.1213/ane.0b013e3181990a82	Thomas C. Mort, MD	Hartford Hospital	USA

LETTERS TO THE EDITOR					
Ref	Title	Published	Performed By	Hospital	Country
LE#2	The Role of Newer Intubation Devices in Difficult Intubation Protocols: A Pan Birmingham Survey.		S Gnanaseakaran	Royal Centre for Defence Medicine, Birmingham.	UK
LE#4	Optical Laryngoscopes – a New Angle on Intubation.	Australian and New Zealand College of Anaesthetists	Anthony Padley	Westmead Hospital, Sydney	Australia.

## 12. Airtraq vs. Other Video L.

MANIKIN STUDIES					
Ref	Title	Published	Performed By	Hospital	Country
MS#7	Pentax-AWS (Airtraq Scope) and Airtraq: big difference between two similar devices.	Journal of Anesthesia 2008, 22:191-192.	Akihiro Suzuki MD	Asahikawa Medical College	Japan
MS#8	A comparative study of Endotracheal Intubation by Airtraq, Glidescope ranger and Direct Laryngoscopy in a Closed Space Environment.	Annals of Emergency Medicine S113, Volume 52, No 4 October 2008.	Hampton MS	Adams BD/San Antonio Health Education Consortium	USA
MS#10	Comparison of the Glidescope , the McGrath , the Airtraq and the Macintosh laryngoscopes in simulated difficult airways* G. L.	Anaesthesia, 2008, 63, pages 1358–1364	Savoldelli et Al.	University of Geneva	Switzerland
MS#11	Comparison of the Airtraq® and Truview® to the Macintosh for use by Advanced Paramedics in easy and simulated difficult intubation in manikins	BMC Emergency Medicine 2009, 9:2	S. Nasim,	Galway University Hospitals, Sligo General Hospital, National University	Ireland
MS#14	Success of Intubation by novice users, a comparison ATQ vs. GS vs. McIntosh	CEMC Abstracts	Ryan G. K. Mihata, MD	Wright State University, Ohio.	USA

## CS#22

### **Tracheal Tube Exchange: Feasibility of Continuous Glottic Viewing with Advanced Laryngoscopy Assistance**

International Anesthesia Research Society DOI: 10.1213/ane.0b013e3181990a82

Thomas C. Mort, MD, Department of Anesthesiology, Hartford Hospital, USA

Seventy-two patients were evaluated, and 51 met the “no view” criteria. Thirty-seven patients had previous difficult intubation

Excellent visualization was possible with each of the three devices, Airtraq, Glidescope and McGrath, in the vast majority of patients.

Visualization of structures was ample for the ETT exchange and confirmation of tracheal reintubation, especially in light of the “no view” offered by conventional laryngoscopy.

Forty-seven of 49 patients (96%) were reintubated on the first attempt.

**This review supports the feasibility of using advanced laryngoscopy for ETT exchange because of its ability to offer a marked improvement in visualizing the periglottic structures in the difficult airway patient.**

## LE#2

### **The role of newer intubation devices in difficult intubation protocols: a Pan Birmingham survey.**

S Gnanaseakaran. Royal Centre for Defence Medicine, Birmingham.

This Pan Birmingham survey was designed to establish which devices are being used, the level of training in their use and whether newer intubation devices have been incorporated into local difficult intubation protocols.

**Methods.** 108 questionnaires were sent.

**Conclusions.** In Birmingham, fiberoptic endoscopy remains the preferred method of managing the 'can mask ventilate, can't intubate' patient. The ILMA was not felt to be particularly easy to use, less than half of the anaesthetists surveyed were trained to use it and it featured in less than 50% of the secondary intubation plans.

Of the newer intubation devices **the Airtraq (30%) was the preferred second choice method of managing difficult intubation.**

**We anticipate that once their value has been proven, these newer intubation devices and techniques will feature in the DAS list of recommended equipment for management of difficult intubation.**



## LE#4

### **Optical Laryngoscopes – A New Angle on Intubation**

Anthony Padley, Westmead Hospital, Sydney, Australia

The four most important types on the Australian market are the GlideScope, CTrach, Pentax-AWS and the Airtraq. **The Airtraq was chosen for use at Westmead Hospital because it is very easy and intuitive to use with intubation achievable in under 20 seconds. They are relatively cheap (\$90 per unit) compared to the outlay required for the CTrach and GlideScope (\$15,000 each). Concerns over deterioration over time of complex components such as LCD screens and cameras are not relevant to the Airtraq.**

The Airtraq has been used successfully in the following situations

- Patients with a **grade 3 direct laryngoscopy** at a previous anaesthetic (3)
- Patients who were not predicted to have a difficult airway **that could not be intubated despite BURP and use of a Teflon bougie** (4).
- A patient with a suspected **cervical spine injury**.
- An **awake intubation** in a patient who had failed a previous intubation attempt at another hospital.
- A patient with **severe facial trauma**.

# MS#7

## **Pentax-AWS (Airtraq Scope) and Airtraq: big difference between two similar devices.**

Journal of Anesthesia 2008, 22:191-192.

Akihiro Suzuki, Asahikawa Medical College, Japan

According to the manufacturer's manual, the AWS tip position should be inserted posterior to the epiglottis, directly elevating it out of the way (Miller-type approach), whereas it is recommended that the **ATQ tip be placed in the vallecula for indirect lifting of the epiglottis (Macintosh-type approach).** For the ATQ, the **Miller-type approach is also possible as an alternative.** But for the AWS, there is no description of an alternative (Macintosh-type) approach.

However, **AWS intubation using a Macintosh-type approach failed in 12 of 15 attempts due to ETT impingement onto the epiglottis, whereas ATQ intubation using the Miller type approach was successful in 15 of 15 attempts** including 3 in which ETT impingement onto the arytenoid occurred, and this was easily solved by blade adjustment

**It seems the ATQ may have an advantage over the AWS because it provides versatility during intubation; with the ATQ, one can use both anterior and posterior routes.**

# MS#8

## **A comparative study of Endotracheal Intubation by Airtraq, Glidescope ranger and Direct Laryngoscopy in a Closed Space Environment.**

Annals of Emergency Medicine S113, Volume 52, No 4 October 2008.

*Uniformed Services Health Education Consortium, San Antonio, TX*

A randomized crossover study was employed to assess the 3 methods of endotracheal intubation on a mannequin secured to the lowest stanchion position of a **UH-60 Blackhawk helicopter** airframe model.

Airtraq (mean = 2.885) was least difficult when compared to GSR (mean = 3.615,  $p = 0.252$ ) and DL (mean = 5.145,  $p = 0.0041$ ).

Intubation times were also improved for the ATQ compared to DL (AT = 23.810s vs. DL = 39.145s,  $P = < 0.0001$ ) and GSR (GSR = 39.295s,  $p = < 0.0001$ ).

Both ATQ and GSR provided significant improvement to CLV as rated by study subjects ( $p = 0.0006$  and  $p = 0.0047$ , respectively).

**Conclusion: The GlideScope Ranger and Airtraq devices enhanced CLV in the closed space setting, and the Airtraq reduced perceived degree of difficulty and reduced time to intubation.**

# MS#10

## **Comparison of the Glidescope, the McGrath, the Airtraq and the Macintosh laryngoscopes in simulated difficult airways**

Anaesthesia, 2008, 63, pages 1358–1364

Savoldelli et Al. University of Geneva

Sixty anaesthesia providers (20 staff, 20 residents, and 20 nurses) were enrolled into this study. The volunteers intubated the trachea of a **Laerdal SimMan manikin in three simulated difficult airway scenarios.**

In all scenarios, indirect laryngoscopes provided better laryngeal exposure than the Macintosh blade and appeared to produce less dental trauma.

In the most difficult scenario (tongue oedema), the Macintosh blade was associated with a high rate of failure and prolonged intubation times whereas indirect laryngoscopes improved intubation time and rarely failed. Indirect laryngoscopes were judged easier to use than the Macintosh.

**The Airtraq consistently provided the most rapid intubation. Laryngeal grade views were superior with the Airtraq and McGrath than with the Glidescope.**

# MS#11

## **Comparison of the Airtraq® and Truview® to the Macintosh for use by Advanced Paramedics in easy and simulated difficult intubation**

BMC Emergency Medicine

Sajid Nasim\*1, Galway University Hospitals, Ireland

**Results:** The Airtraq® reduced the number of optimization manoeuvres and reduced the potential for dental trauma when compared to the Macintosh, in both the normal and simulated difficult intubation scenarios. In contrast, the Truview® increased the duration of intubation attempts, and required a greater number of optimization manoeuvres, compared to both the Macintosh and Airtraq® devices.

**Conclusion: The Airtraq® laryngoscope performed more favourably than the Macintosh and**

**Truview® devices** when used by Paramedics in this manikin study. Further studies are required to

extend these findings to the clinical setting.

# MS#14

## **Success of endotracheal intubation by novice users: a comparison of Glidescope, Airtraq and Macintosh laryngoscopes**

CEMC Abstracts 205

Ryan, Mihata,, Wright State University, Centerville, Ohio.

**48 medical students with no prior intubation experience.** Each student intubated a manikin with each of the three devices in four scenarios: normal airway, difficult airway (cervical spine immobility), difficult airway (pharyngeal swelling), and repeat normal airway.

**Airtraq and Glidescope were consistently rated easier to use than the Macintosh.** In most scenarios, **Airtraq was rated easier to use than Glidescope.**

**Conclusion:** For novice users, Airtraq and Glidescope show significant advantages in time to intubation as well as perceived ease-of use when compared to direct laryngoscopy. **Airtraq outperformed Glidescope in most scenarios.** We saw improvement in time to intubation as well as ease-of-use over a short training period.